



RESEARCH ARTICLE

Hepatoprotective Effect of Oyster Mushroom (*Pleurotus Sajor Caju*) in Broilers Fed Aflatoxin

R. Yogeswari^{1*}, S. Murugesan² and A. Jagadeeswaran¹

¹Department of Veterinary Pharmacology and Toxicology, Veterinary College and Research Institute, Namakkal-2, Tamilnadu; ²Veterinary University Training and Research Centre, Salem, Tamilnadu, India

ARTICLE INFO

Received: September 29, 2012

Revised: October 07, 2012

Accepted: October 17, 2012

Key words:

Aflatoxin

Antioxidant

Hepatoprotective

Oyster mushroom

Pleurotus sajor caju

*Corresponding Author

R. Yogeswari

yogamvsc@yahoo.co.in

ABSTRACT

The present study was undertaken to evaluate the hepatoprotective effect of oyster mushroom (*Pleurotus sajor caju*) against aflatoxicosis in straight run broiler chicken (Vencob strain). Liver damage was assessed by quantifying the levels of serum proteins, Alanine aminotransferase (ALT), Aspartate aminotransferase (AST) and antioxidant profile which included lipid peroxidation, Glutathione peroxidase (GPx) and Superoxide dismutase levels (SOD) supported by gross and histopathological examination. Aflatoxin administration at 1 ppm level resulted in increase in serum ALT and AST, decrease in serum proteins, increase in lipid peroxidation and decrease in GPx and SOD levels with varying degrees of liver damage ranging from macrovesicular degeneration of hepatocytes to bile duct hyperplasia. Oyster mushroom (1%, 2.5% and 5% levels) produced dose dependant improvement in all the parameters studied indicating hepatoprotective effect.

Cite This Article as: R. Yogeswari, S. Murugesan and A. Jagadeeswaran, 2012. Hepatoprotective Effect of Oyster Mushroom (*Pleurotus Sajor Caju*) in Broilers Fed Aflatoxin. Inter J Vet Sci, 1(3): 104-107. www.ijvets.com

INTRODUCTION

Aflatoxins are secondary metabolites produced by certain fungi belonging to the genus *Aspergillus*. Aflatoxins are produced in feed stuff, when appropriate conditions of humidity and temperature exist during storage (Fernandez *et al.*, 1994). Consumption of such toxin contaminated feed poses great hazards to poultry health by causing liver damage, retarded growth, impaired feed conversion and immune suppression through depression of both cell mediated and humoral immunity (Shivachandra *et al.*, 2003).

Six hundred and fifty one species representing one hundred and eighty two genera of hetero and homobasidiomycetes mushrooms have been found to contain antitumor or immune stimulating polysaccharides. There are many other beneficial effects found in mushrooms, such as antioxidant (Lakshmi *et al.*, 2005), hypoglycemic, anti-inflammatory and hepatoprotective activities (Leifa Fan *et al.*, 2000 and Jayakumar *et al.*, 2006).

Hence in the present study, the hepatoprotective effect of *Pleurotus sajor caju* was assessed against experimental aflatoxicosis in broilers by evaluating serum biochemical parameters, antioxidant profile and pathological alterations of liver.

MATERIALS AND METHODS

The experiment was conducted as per the guidelines of the Institutional Animal ethical committee.

Aflatoxin B₁ was produced on sterile rice using *Aspergillus parasiticus* NRRL 2999 strain (Shotwell *et al.*, 1966) and estimated by Romer method (1975) using Thin Layer Chromatography. Oyster mushroom was purchased from a commercial production unit at Coimbatore, India, shade dried and powdered. The toxin and mushroom powder were mixed with the feed in appropriate quantities according to experimental design.

Sixty commercial day old straight run broiler chicks (Vencob strain) were weighed, wing banded and reared under standard management conditions. The chicks were fed standard broiler feed free of aflatoxin and water *ad libitum* during the first week. On day eighth, the chicks were randomly divided into six treatment groups of ten each and the following treatment was given from the eighth day to forty second day.

Group I was fed with normal feed (control). Aflatoxin (1ppm) mixed feed was given to group II (Aflatoxin control). Group III was fed with mushroom (5%) mixed feed (mushroom control). Aflatoxin 1ppm along with 1%, 2.5% and 5% mushroom was mixed with feed and fed to groups IV, V and VI respectively.

The birds were sacrificed on 42nd day of age. Gross pathology of liver was studied. Blood samples were collected for estimation of serum protein, Alanine aminotransferase, Aspartate aminotransferase by colorimetric method (Reitman and Frankel, 1957) and lipid peroxidation by Thiobarbituric acid- reacting substances method (Ohkawa *et al.*, 1979). Liver samples were collected, washed in saline, kept in freezer for the estimation of Glutathione peroxidase (Rotruck *et al.*, 1973) and Superoxide dismutase (Marklund and Marklund, 1974) and in 10% buffered neutral formalin for histopathological studies.

Data were subjected to statistical analysis as per Snedecor and Cochran (1989) by Completely Randomized Design.

RESULTS AND DISCUSSION

Serum biochemical changes

Aflatoxin treatment resulted in highly significant ($P \leq 0.01$) decrease in serum proteins, albumin and globulin (Table 1). This decrease might be due to binding of aflatoxin metabolite to DNA, disrupting transcriptional events leading to inhibition of protein synthesis. (Huff *et al.*, 1986)

Mushroom treatment resulted in significant ($P \leq 0.01$) ** increase in serum total protein compared to that of group II. The restorative effect exhibited by mushroom may be due to its high protein content (Cohen *et al.*, 2002 and Rajini Goyal *et al.*, 2006). In addition the mushroom also contains basic antioxidant compounds namely ascorbic acid, Vitamin C, Vitamin E, β carotene and phenolic compounds (Yang *et al.*, 2002). Hence the restoration may be due to the hepatoprotective effect of mushroom against aflatoxin B₁.

The ALT and AST values were found to be significantly ($P \leq 0.05$) elevated in aflatoxin alone fed group (Table 1) indicating interruption in liver function. Mushroom treatment resulted in a dose dependant significant decrease in ALT and AST compared to that of group II. The ability of the mushroom to inhibit CYP1A activities might prevent the epoxide formation from aflatoxin B₁, reducing the hepatic damage (Khlood *et al.*, 2005).

Antioxidant profile

A significant increase in lipid peroxidation ($P \leq 0.05$) and decrease in Glutathione peroxidase ($P \leq 0.01$) and Superoxide dismutase ($P \leq 0.05$) was recorded in aflatoxin alone fed group (Table 1). Among the treatment groups there was a dose dependant significant decrease in lipid peroxidation and increase in SOD and GPx activities. *Pleurotus* species play a major role in inhibiting lipid peroxidation due to aflatoxin feeding (Nayana Jose and Janardhanan, 2000). In addition to this *Pleurotus* species contains basic antioxidant compounds namely ascorbic acid, Vitamin C, Vitamin E, β Carotene and phenolic compounds (Yang *et al.*, 2002) which might be responsible for reducing the oxidation process due to aflatoxin feeding.

Gross Pathology

In aflatoxin control group the liver was enlarged, friable and pale. In addition, ascites and enlargement of kidney were observed.

Mushroom treatment at 1% level resulted in moderate enlargement and congestion of liver. Mushroom treatment at 2.5% and 5% resulted in almost normal appearance of liver indicating hepatoprotective effect.

Histopathology

The liver from mushroom control group showed normal histology (Plate I).

The results of histopathological studies of liver from aflatoxin fed group revealed macrovesicular changes, replacement of necrosed hepatocytes by infiltrating mononuclear cells, bile duct hyperplasia (Plate II) and central venous congestion. In addition to these changes, pseudo acini formation and microcyst formation were also noticed.

Among the treatment groups, liver from group IV, showed diffuse necrosis of hepatocytes, pseudo acini formation, infiltration of mononuclear cells, macro and micro vesicular changes, venous congestion and disruption of hepatic cords (Plate III).

Table 1: Effect of oyster mushroom (*Pleurotus sajor caju*) on serum biochemical parameters and antioxidant profile (mean \pm S.E) in aflatoxin fed broilers (n=6)

Group	Total protein** g/dl	Albumin** g/dl	Globulin* g/dl	ALT (SGPT)* Units/ml	AST (SGOT)* Units/ml	Lipid peroxidation* nmol/ml	Glutathione peroxidase** mg of GSH consumed /min/mg of protein	Superoxide dismutase* Units/min/ mg of protein
Control	5.88 ^a \pm 0.13	1.71 ^a \pm 0.06	4.17 ^a \pm 0.16	13.33 ^b \pm 1.23	126.33 ^c \pm 5.74	31.20 ^b \pm 0.95	18.93 ^a \pm 0.09	1.22 ^a \pm 0.01
AFB1 1ppm	4.83 ^b \pm 0.21	1.21 ^c \pm 0.04	3.62 ^b \pm 0.22	20.00 ^a \pm 0.89	148.00 ^a \pm 4.47	41.99 ^a \pm 4.67	13.76 ^a \pm 0.17	0.76 ^d \pm 0.01
Mushroom 5%	5.84 ^a \pm 0.16	1.77 ^a \pm 0.06	4.07 ^a \pm 0.18	14.00 ^b \pm 1.46	132.00 ^{bc} \pm 3.79	31.63 ^b \pm 1.24	18.49 ^{ab} \pm 0.17	1.23 ^a \pm 0.01
AFB1 1 ppm + Mushroom 1%	5.65 ^a \pm 0.13	1.53 ^b \pm 0.02	4.12 ^a \pm 0.13	16.67 ^{ab} \pm 1.69	141.67 ^{ab} \pm 5.90	33.37 ^b \pm 1.24	15.39 ^d \pm 0.21	1.03 ^c \pm 0.01
AFB1 1 ppm + Mushroom 2.5%	5.93 ^a \pm 0.13	1.62 ^{ab} \pm 0.04	4.31 ^a \pm 0.14	15.33 ^b \pm 1.33	131.00 ^{bc} \pm 6.17	31.63 ^b \pm 1.83	17.18 ^c \pm 0.21	1.14 ^b \pm 0.02
AFB1 1 ppm + Mushroom 5%	5.98 ^a \pm 0.11	1.63 ^a \pm 0.04	4.35 ^a \pm 0.13	14.67 ^b \pm 1.23	129.00 ^{bc} \pm 4.02	31.20 ^b \pm 1.50	18.07 ^{bd} \pm 0.18	1.20 ^a \pm 0.01

*Overall mean bearing different superscripts between rows differ significantly ($P \leq 0.05$); **Overall mean bearing different superscripts between rows differ significantly ($P \leq 0.01$)

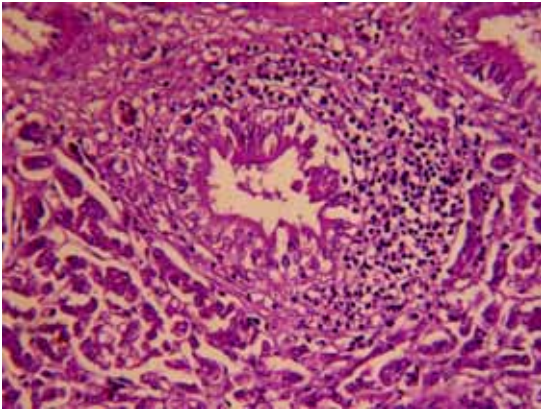


Plate I: Normal portal vein and hepatocyte – Mushroom control. H&E X 400

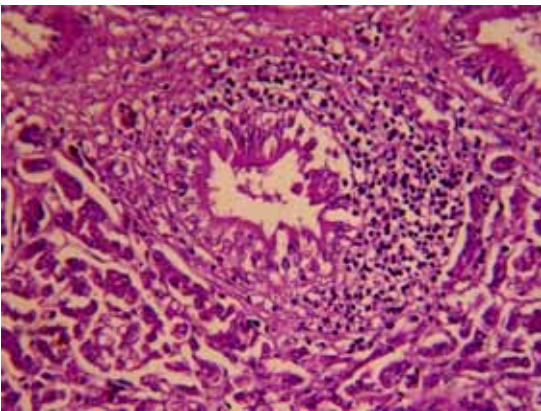


Plate II: Hyperplastic bile duct surrounded by mononuclear inflammatory cells – Aflatoxin control. H&E X 400

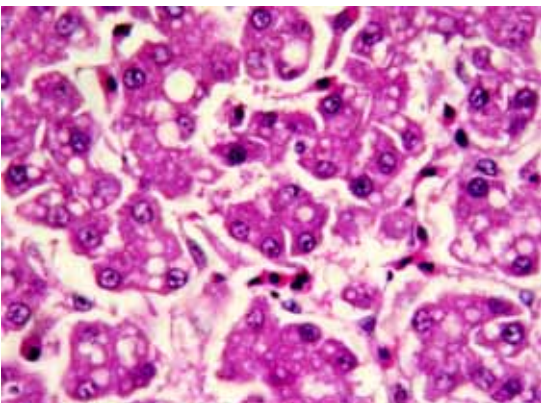


Plate III: Pseudo acini formation and moderate vesicular changes of hepatocytes–Aflatoxin 1 ppm + Mushroom 1% H&E X 400

While group V showed infiltration of inflammatory cells, focal necrosis of hepatocytes and cloudy swelling of surrounding cells (Plate IV), group VI showed only microvesicular changes and slight disruption of hepatic cords (Plate V).

Among the treatment groups, a dose dependant improvement in the hepatic architecture was observed. *Pleurotus ostreatus* mushroom administration to the rats

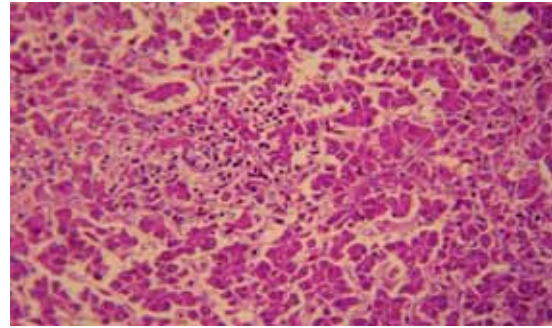


Plate IV: Disruption of cords, micro vesicular changes of hepatocytes and sinusoidal infiltration of inflammatory cells - Aflatoxin 1 ppm + Mushroom 2.5% H&E X 400

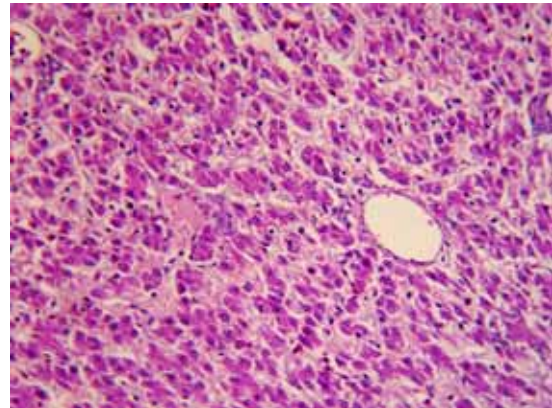


Plate V: Normal central vein and slight disruption of hepatic cords - Aflatoxin 1 ppm + Mushroom 5% H&E X 400

with hepatic damage induced by CCl_4 , resulted in only minimal disruption of hepatic cellular structure (Jayakumar *et al.*, 2006).

These results indicate the hepatoprotective effect of the mushroom. Hence the present study is suggestive of substantial reversal of aflatoxin induced hepatotoxicity by *Pleurotus sajor caju* mushroom in a dose dependant manner.

Acknowledgement

The authors wish to thank the authorities of Tamilnadu Veterinary and Animal Sciences University, Chennai, India, for the financial support given.

REFERENCES

- Cohen, R, L Persky, and Y Hadar, 2002. Biotechnological application and potential of wood-degrading mushrooms of genus *Pleurotus*. Appl. Microbiol and Biotechnol, 58(5): 582-594.
- Fernandez, A, Maria Teresa Verde, M Gascon, J Ramos, J Gomez, DF Luco, and G Chavez, 1994. Variations of clinical biochemical parameters of laying hens and broiler chickens fed aflatoxin containing feed. Avian Pathol, 23, 37-47.
- Huff, WE, LF Kubena, RB Harvey, DE Corrier and HH Mollen Hauer, 1986. Progression of aflatoxicosis in broiler chickens. Poul. Sci, 65, 1891- 1899.
- Jayakumar, T, E Ramesh, and P Geraldine 2006. Antioxidant activity of the oyster mushroom *Pleurotus*

- ostreatus* on CCl₄ induced liver injury in rats. Food. Chem. Toxicol, 44(12), 1989-1996.
- Khlood, M, EL Bohi, Laila Sabika, Kaampwe Muzandu, Zein shaban, Mohamed Soliman, Mayumi Ishizuka, Akio Kazusaka and Shoichi Fujita, 2005 Antigenotoxic effect of *Pleurotus cornucopiae* extracts on the mutagenesis of *Salmonella tyhimurium* TA98 elicited by benzo[a]pyrene and oxidative DNA lesions in V79 hamster lung cells. Jpn. J. of Vet. Res, 52(4), 163-172.
- Lakshmi, B, JC Tilak, S Adhikari, TPA Devasagayam, and KK Janardhanan, 2005. Inhibition of lipid peroxidation induced by γ - radiation and AAPH in rat liver and brain mitochondria by mushrooms. Curr. Sci, 88(3), 484-488.
- Leifa Fan, Huijuan Pan, Andrea Thomaz Soccol, Ashok Pandey and Carlos Ricardo Soccol, 2000. Advances in Mushroom Research in the Last Decade. Food Technol. Biotechnol, 44(3), 303-311.
- Marklund, S and G Marklund, 1974. SOD activity assay by the method of pyrogallol. Eur. J. Gerontol, 17, 429-437.
- Nayana Jose and KK Janardhanan, 2000. Antioxidant and antitumor activity of *Pleurotus florida*. Curr. Sci, 79(7), 941-943.
- Ohkawa, H, N Ohishi, K and Yagi, 1979. Assay of lipid peroxides in animal tissue by Thiobarbituric acid reaction. Anal. Biochem, 95, 351-358.
- Rajni Goyal, RB, RK Grewal, and Goyal, 2006. Nutritional attributes of *Agaricus bisporus* and *Pleurotus sajor caju* mushrooms. Nutr. Health, 18(2), 179-184.
- Romer, TR, 1975 Qualitative/quantitative analysis for detection and estimation of aflatoxin. (Romi mini column method). Journal of Association of Official Anal. Chem, 58, 500-503.
- Rotruck, JR, A Pope, and HE Ganther, 1973 Selenium-biochemical role as a component of glutathione peroxidase purification and assay. Science, 17, 486-490.
- Reitman, S and S Frankel, 1957. A colorimetric method for the determination of ALT and AST. Am. J. Clin. Pathol, 28, 56-636.
- Sendecor, GW and WG Cochran, 1989. Statistical methods, 8th Edn. IOWA state Univ. Press. Ames.
- Shivachandra, SB, RL Shah, SD Singh, TS Johri and K Manimaran, 2003. Pathobiochemical and immunological changes in experimental aflatoxicosis. Indian J. Poult. Sci, 38(2), 137-141.
- Shotwell, OL, CW Hesseltine, RD Stabblefield and GW Sorenson, 1996 Production of aflatoxin on rice. Appl Microbiol, 14, 425-428.
- Yang, JH, HC Lin and JL Mau, 2002. Antioxidant properties of several commercial mushrooms. Food. chem, 77, 229-235.