



RESEARCH ARTICLE

Radiographic Evaluation of Acellular Matrix of Swim Bladder for Augmentation Cystoplasty in Rabbits

K Lavanya¹, Makkena Sreenu², V Devi Prasad³, K Suresh⁴, PAnadkumar⁵ and P Jagapathiramayya⁶

¹Department of Veterinary Surgery & Radiology, NTR College of Veterinary Science, Gannavaram – 521 101(AP), India

²Teaching Veterinary Clinical Complex, College of Veterinary Science, Korutla, Karimnagar (dt) 505 326

³Department of Veterinary Surgery & Radiology, ⁴Department of Veterinary Microbiology, ⁵Department of Veterinary Anatomy and Histology, College of Veterinary Science, Proddatur, Kadapa (Dt) AP

⁶Sri Venkateswara Veterinary University Tirupati

ARTICLE INFO

Received: March 06, 2014

Revised: June 21, 2014

Accepted: August 08, 2014

Key words:

Acellular matrix

Cystoplasty

Rabbits

Swim bladder

*Corresponding Author

Makkena Sreenu

drmakkena@yahoo.co.in

ABSTRACT

The present investigation was aimed to study the efficacy of the acellular swim bladder graft for augmentation cystoplasty in rabbits. A total of 24 rabbits of either sex divided in to three groups; augmentation cystoplasty with autogenous bladder graft, fresh acellular swim bladder and acellular swim bladder graft, following partial cystectomy procedure. Post operatively Lateral and ventrodorsal plain and contrast retrograde cystography studies were performed in live rabbits by using urographin material on 7th, 14th, 21st and 28th of postoperative day to study the patency of the reconstructed urinary bladder. Pneumoperitoneography is also conducted for better visualization of the abdomen. The acellular swim bladder was well accepted by the host tissue and is ideal for augmentation cystoplasty rabbits followed by auto graft and fresh swim bladder graft.

Cite This Article as: Lavanya K, M Sreenu, VD Prasad, K Suresh, PA Kumar and P Jagapathiramayya, 2014.

Radiographic evaluation of acellular matrix of swim bladder for augmentation cystoplasty in rabbits. Inter J Vet Sci, 3(4): 198-202. www.ijvets.com

INTRODUCTION

Researches dedicated to the regeneration of urinary bladder have been evolved in parallel with progress in the management of bladder diseases. The first historical report on the regeneration of bladder tissue on autologous fascia was published in 1917 by Neuhof. Augmentation ileocystoplasty was first described in the dog by Tizzoni and Foggi in 1888 and in man by Von Mikuliczin in 1889 (Greenwell *et al.*, 2001). The introduction of gastrocystoplasty followed later with initial reports in dogs by Sinaiko in 1956, and translation into human by Leong in 1978. Studies in rabbits and dogs showed that bladder augmentation with acellular matrices or biodegradable polymers provided better results when they were seeded with urothelial cells or bladder smooth muscle cells and urothelial cell (Moshe and Amiel, 2008). The present study aimed to investigate the efficacy of the different bladder grafts for its augmentation.

MATERIALS AND METHODS

The present study was conducted on twenty four rabbits (n=24) of either sex in the age group of 1-2 years

and weighing between 1.5-2 kg following approval from Institutional Animal Ethics committee. They were determined to be healthy on the basis of physiological and hemato-biochemical parameters. All the rabbits were dewormed with Fenbendazole (20 mg/kg orally during one week) prior to the study and maintained under identical managemental conditions. A total of 24 rabbits of either sex divided in to three groups were used for augmentation; cystoplasty with autogenous bladder graft (Group I), fresh acellular swim bladder (Group II), and acellular swim bladder graft (Group III), following laparotomy routine cystotomy and partial cystectomy. Acellular swim bladder grafts were prepared by decellularizing the Fresh swim bladders using 1M sodium chloride solution and 0.5% Triton X-100 under gentle agitation. All the rabbits were premedicated with Triflupromazine hydrochloride (1mg/ kg, im). The rabbits were anesthetized using Thiopental (10-20 mg/kg, iv via auricular ear vein). They were placed on dorsal recumbency and extended the both hind limbs for proper access to operative site. Postoperatively all the animals were administered with injection enrofloxacin 5mg/kg im and meloxicam suspension 0.2mg/kg orally for five days and the surgical wound was dressed in a routine manner.

The augmented bladder was drained by a Foley catheter for at least 2 weeks following surgery. The animals were maintained under a 12-h alternating light dark cycles with freely available food and water without urinary diversion or drains. Lateral ventrodorsal positing plain and contrast retrograde cystography were performed in live rabbits by using urographin material on 7th, 14th, 21st and 28th of postoperative day to study the patency of the reconstructed urinary bladder. The percentage of shrinkage was estimated in this study the rabbits were subjected to retrograde catheterization in both sex. After catheterization the urographin material was injected into the bladder through the catheter. Pneumoperitoneography is also conducted for better visualization of the abdomen procedure.

RESULTS AND DISCUSSION

Restraining the animals in lateral and dorsal recumbancy for lateral and ventro dorsal views respectively provided better positioning for plain as well as contrast studies. Radiographic results about the groups were summarized in Table 1. In Group I, cystography on 7th postoperative day did not show any evidence of leakage of urine indicating the intactness of the graft. The vesico urethral reflux persisted but did not progress. The urinary bladder was in normal size and configuration had not any diverticulum or fistula. The bladders had a normal round contour in one animal but in another animal it has been shaped. Cystograms on this day showed inconsistent augmentation effect with smooth-walled bladder. Pneumo-peritoneography demonstrated the visceral organs of the peritoneal cavity without any gross changes (Fig. 1). Contrast cystography conducted on 14th postoperative day, revealed the intactness of the graft as there was absence of urine leakage. Cystography in two animals showed compromised size and configuration of the urinary bladder without any diverticulum or fistula. The bladders had a trigone shape with irregular contour. The reconstructed part of the bladder wall showed bulging. Cystograms obtained on this day demonstrated inconsistent augmentation effect with irregular wall and contraction of the bladder dome (Fig. 2). Retrograde Contrast cystography performed on 21st postoperative day did not show any evidence of urinary leakage. Cystography in two animals showed compromised size

and configuration of urinary bladder without any diverticulum or fistula. The bladders had a spindle shape with irregular contour. The vesico urethral reflux persisted but did not progress. The reconstructed part of the bladder wall showed bulging. Reconstructed urinary bladders showed inconsistent augmentation effect with irregular wall and contraction of the bladder dome on this day of observation (Fig. 3). Retrograde Contrast cystography on 28st postoperative day did not show any evidence of urinary leakage. Cystography in two animals showed considerable size and configuration of the urinary bladder without any diverticulum or fistula. The bladders had an elongated balloon shape with dorsal irregular contour. The vesiculo urethral reflux was slightly persisted. The reconstructed part of the bladder wall showed undulated surface. Cystograms taken after reconstruction showed considerable augmentation effect with scarring and contraction of the bladder dome (Fig. 4).

In Group II, Cystography performed on 7th postoperative day, did not show any evidence of urinary leakage. Post operatively, the reflux persisted, but did not progress. Cystography in two animals showed normal in size and configuration of urinary bladder without any diverticulum or fistula. The bladders had a normal contour but had a mushroom shape at grafted site revealing detachment of the graft. Cystograms taken after reconstruction showed consistent augmentation effect with smooth-wall. Pneumoperitoneography demonstrated the visceral organs of the peritoneal cavity without any gross changes (Fig. 5). Contrast cystography conducted on 14th postoperative day did not show any evidence of urinary leakage. Cystography in two animals showed compromised size and configuration urinary bladder without any diverticulum or fistula. The bladders had a trigone shape with regular contour. The reconstructed bladders showed partial augmentation effect with regular bladder wall (Fig. 6). On 21st postoperative day cystography in two animals showed almost the normal size and configuration of the urinary bladder with inpouching of the wall. There was no evidence of any diverticulum or fistula. The bladders had a mush room shape with irregular contour. Thickening and increased opacity of the grafted site were the findings. The reconstructed area of the bladder wall showed improper alignment and contour. Inconsistent augmentation effect

Table 1: Radiological results of cystoplasty in rabbits (N=8)

	Group I days				Group 2 days				Group 3 days			
	7	14	21	28	7	14	21	28	7	14	21	28
Intactness of the graft	+	+	+	+	-	+	+	+	+	+	+	+
Size	N	S	Nl	N	N	S	N	Md	N	N	N	N
Configuration	R	R	IR	R	R	R	R	R	IR	IR	R	R
Diverticulum	-	-	-	-	-	-	-	-	-	-	-	-
Fistula	-	-	-	-	-	-	-	-	-	-	-	-
Shape	B	T	S	E	D	R	M	T	ML	T	S	T
Dome	-	-	C	S	-	-	R	R	-	-	U	N
Augmentation	C	IC	IC	C	CS	PI	IC	CS	CM	PI	CL	CS
Bladder wall	-	-	-	S	IT	IT	IT	-	IT	-	-	-
Any others	-	-	-	-	-	-	-	-	-	-	-	-

Intactness of the graft: + Present; - Absent) Size: N=Normal; S=Small; Md= Moderate Configuration: R = regular IR= Irregular; Shape: B=Bean T= Trigone S=Spindle E= Elongated and balloon D=dome R=round M=Mush room ML= Multi lobular; Dome: C=Constricted S= scarring R=round U= uniform N= normal Augmentation: C=consistent IC=Inconsistent CS=Considerable P=partial CM=complete CL= clear Bladder wall: S= squaring IT= increased thickness

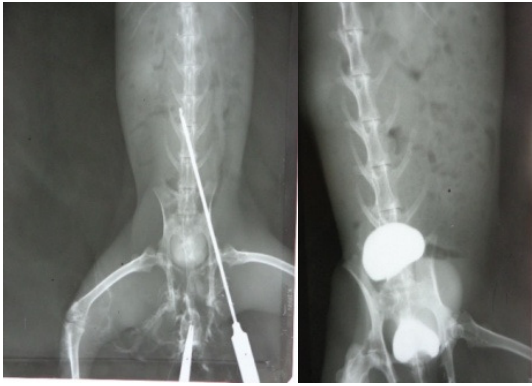


Fig. 1: Pneumoperitoneography (A) and Cystography (B) demonstrating the intact autograft following Cystoplasty in rabbits at 7th postoperative day (Ventrodorsal view)

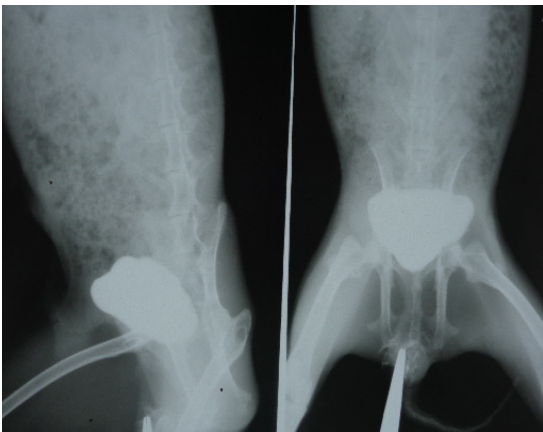


Fig. 2: Positive Contrast retrograde Cystography demonstrating the intact auto graft following Cystoplasty in rabbits at 14th post operative day (lateral and Ventrodorsal view)

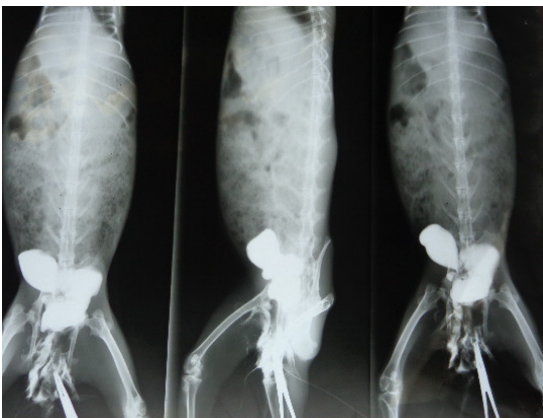


Fig. 3: Positive Contrast retrograde Cystography demonstrating the auto graft following Cystoplasty in rabbits at 21st post operative day (Ventrodorsal and lateral view)

with irregular wall and contraction of the bladder dome were the findings recorded (Fig. 7). Contrast cystography performed on 28th postoperative day did not show any evidence of urinary leakage. Cystography in two animals showed moderate size with configuration of urinary bladder without any diverticulum or fistula. The bladders had a trigone shape with rounded dome. Considerable

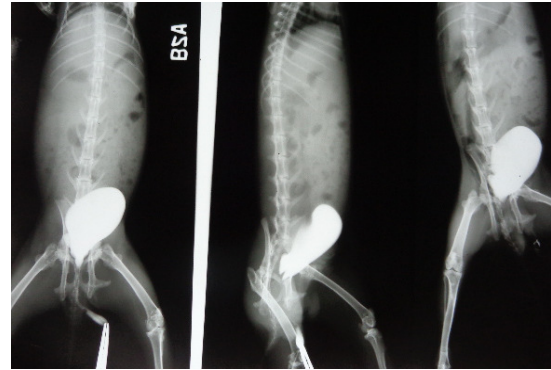


Fig. 4: Positive Contrast retrograde Cystography demonstrating the autograft following Cystoplasty in rabbits at 28th post operative day (Ventrodorsal and lateral view)

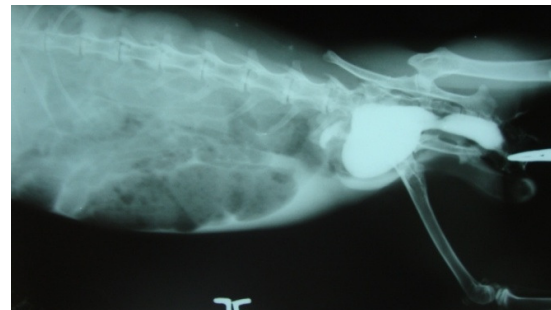

Fig. 5: Positive Contrast retrograde Cystography demonstrating the detached fresh swim bladder graft following Cystoplasty in rabbits at 7th post operative day (Lateral View)

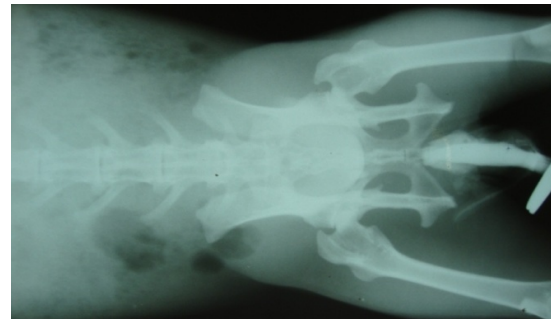


Fig. 6: Positive Contrast retrograde Cystography demonstrating the intact fresh swim bladder graft following Cystoplasty in rabbits at 14th post operative day (Ventrodorsal view)

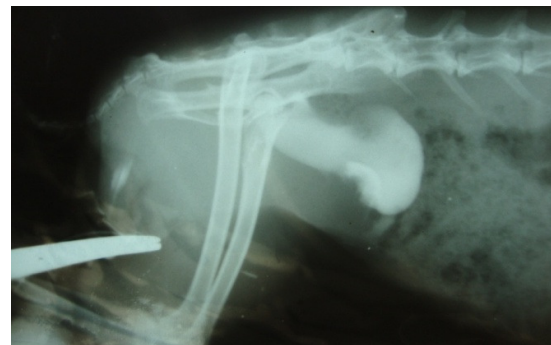

Fig. 7: Positive Contrast retrograde Cystography demonstrating the Fresh swim bladder following Cystoplasty in rabbits at 21th post operative day (lateral view)

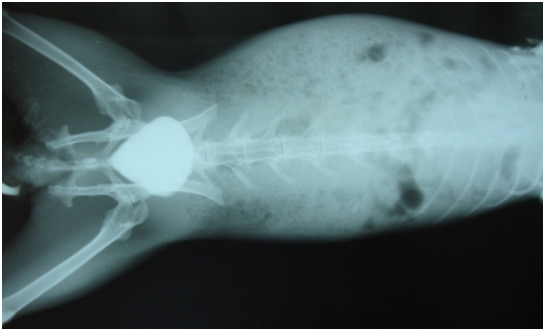


Fig. 8: Positive Contrast retrograde Cystography demonstrating the Fresh swim bladdergraft following Cystoplasty in rabbits at 28th post operative day (Ventrodorsal and lateral view)

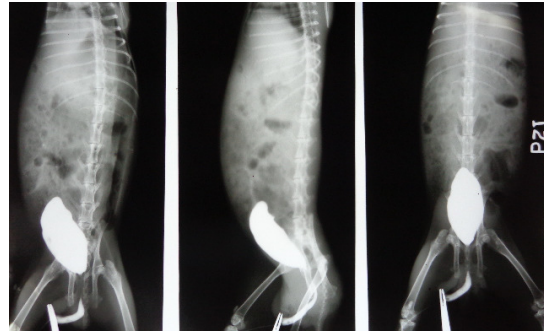


Fig. 11: Positive Contrast retrograde Cystography demonstrating the acellular swim bladder following Cystoplasty in rabbits at 21th post operative day (Ventrodorsal and lateral view)

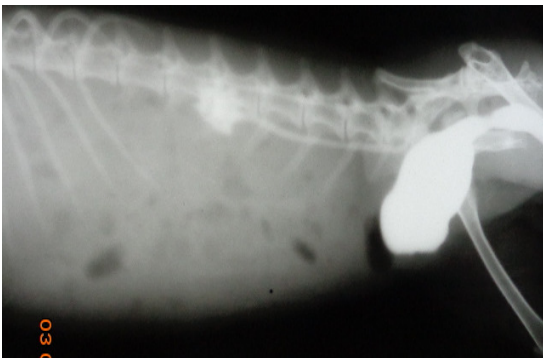

Fig. 9: Positive Contrast retrograde Cystography demonstrating the Intact acellular swim bladder graft following Cystoplasty in rabbits at 7th post operative day (Ventrodorsal and Lateral view)

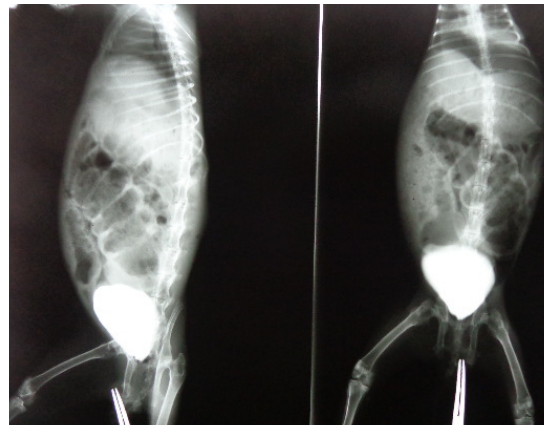


Fig. 12: Positive Contrast retrograde Cystography demonstrating the acellular swim bladdergraft following Cystoplasty in rabbits at 28th post operative day (Lateral and Ventrodorsal view)

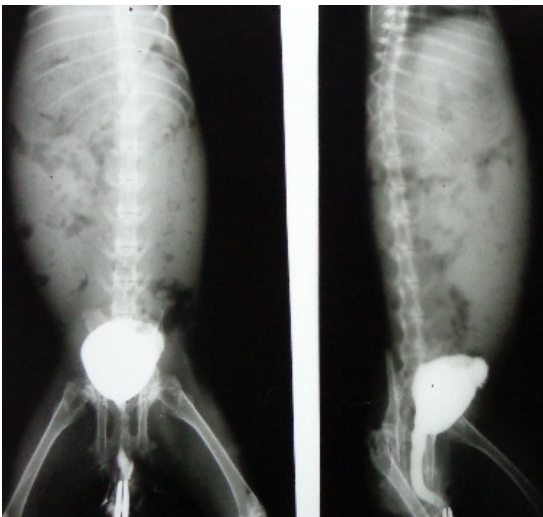


Fig. 10: Positive Contrast retrograde Cystography demonstrating the intact acellular swim bladder graft following Cystoplasty in rabbits at 14th post operative day (Ventrodorsal and lateral view)

augmentation effect without any scarring and contraction of the bladder dome of reconstructed urinary bladder were observed (Fig. 8).

In Group III, Contrast cystography on 7th postoperative day revealed the intactness of the graft without any diverticulum or fistula. The vesico urethral reflex persisted post operatively. Cystography showed normal size and irregular configuration of urinary bladder.

The bladders had an elongated multilobulated appearance with irregular dome. Cystograms demonstrated complete augmentation effect with ragged wall of urinary bladder (Fig. 9). Retrograde Contrast cystography of two animals on 14th postoperative day showed considerable size and configuration of urinary bladder without any diverticulum or fistula. The bladders had a trigone shape with irregular contour. The grafted part appeared as areas of radioleucency with increased opacity. The graft showed more radioopacity than the bladder wall. Cystograms revealed partial augmentation effect with irregular wall (Fig. 10). On 21st postoperative day retrograde contrast cystography of two animals showed almost the normal size and configuration with uniform dome. There was no evidence of any diverticulum or fistula. The bladders had a spindle shape with regular contour (Fig. 11). The reconstructed part of the bladder wall showed proper alignment and contour. There was a clear augmentation effect with regular wall without contraction of the bladder dome in reconstructed bladders. The urinary bladder, following injection of contrast material on 28th postoperative day, showed normal size and configuration without any diverticulum or fistula. The bladders had a trigone shape with rounded dome. The reconstructed urinary bladders showed considerable augmentation effect with round configuration closely resembling the preoperative state with even filling. The bladder did not

reveal any scarring and contraction of the bladder dome (Fig. 12).

Restraining the animals in lateral and dorsal recumbency for lateral and ventro dorsal views respectively in the present study provided better positioning for plain as well as contrast studies as reported by Kropp *et al.* (1996). Use of urographin as positive contrast material in the present study achieved better alienation of the urinary bladder to study the changes of the reconstructed part of urinary bladder on the contrary Ramesh Kumar (1995) conducted contrast cryptographic studies using 10% barium suspension. Pneumoperitoneography was performed to assess the details of the peritoneal cavity position, contour, shape and any leakages of urinary bladder as reported by Ranganath and Mahesh (2009).

Urocystography at different periods in group I revealed intactness of the graft in all the animals. The vesico urethral reflux persisted but did not progress. The urinary bladder showed different sizes and configuration without any diverticulum or fistula. Cystograms showed inconsistent augmentation effect in the early period as time progresses it was considerable. Retrograde cystography at different periods in group II revealed intactness of the graft in all the animals. The urinary bladder showed mush room and trigone shapes without any diverticulum or fistula. Cystograms showed partial augmentation effect in early period it was considerable as as time progresses while the group III animals showed normal size, regular configuration and considerable augmentation effect at any period of observation showing its superiority among the other grafts. Contrast radiography is considered to be one of the best procedures to evaluate the urinary bladder following reconstruction. Ramesh Kumar (1995); Kropp *et al.* (1996); Dahms *et al.* (1998); Probst *et al.* (2000); Close *et al.* (2001); Brehmer *et al.* (2006) and Crandis *et al.* (2010) conducted contrast radiography to evaluate the urinary bladder size, shape, contour and augmentation effect as followed in the present study.

In conclusion the acellular swim bladder was well accepted by the host tissue and is ideal for augmentation cystoplasty rabbits followed by auto graft and fresh swim bladder graft. However the fresh swim bladder graft has the drawbacks of complications including wound healing, more adhesion formation and more tissue reaction. Because of early degradation of scaffold with deposition of native tissue, proliferation of epithelium, along with high degree of angiogenesis and lesser inflammatory

reaction, acellular swim bladder graft can be graded superior to autograft and the fresh swim bladder grafts.

Acknowledgement

The financial assistance received under the DBT Research Project on "Development and evaluation of Acellular biomaterial of marine origin for tissue repair in bovine" from Department of Biotechnology, Ministry of Science and Technology, New Delhi is gratefully acknowledged.

REFERENCES

- Brehmer B, D Rohrmann, G Rau and G Jakse, 2006 Bladder Wall Replacement by Tissue Engineering and Autologous Keratinocytes in Mini pigs BJU Inter, 97: 829-836.
- Close CE, PA Dewan, PJ Ashwood, RJ Byard and ME Mitchell, 2001. Auto augmentation Peritoneocystoplasty in a Sheep Model BJU Inter, 88: 414-417.
- Crandis *et al.*, 2010. Bladder autoaugmentation in the rabbit using deepithelialized segment of small intestine, stomach and lyophilized human duramatter. Biomed Mat Res, 32: 734-738.
- Dahms SE, HJ Hans J Piechota, R Dahiya, CA Gleason, M Hohenfellner and EA Tanagho, 1998. Bladder acellular matrix graft in rats:its neurophysiologic properties and mRNA expression of growth factors TGF-a and TGF-b NeuroUrol Urodyn, 17: 37-54.
- Greenwell TI, SN Venn and AR Mundy, 2001. Augmentation cystoplasty. BUN inter, 88: 511.
- Kropp BP, MK Rippey, SF Badylak, MC Adams, MA Keating, RC Rink and KB Thor, 1996. Regenerative urinary bladder augmentation using small intestinal submucosa: Urodynamic and histopathologic assessment in long-term canine bladder augmentations. J Urol, 155: 2098-2104.
- Moshe BY, GE Amiel, 2008. Biocompatible materials for bladder substitution. Brit J Urol Inter, 102: 1334-1338.
- Probst M, HJ Piechota, R Dahiya and EA Tanagho, 2000. Homologous bladder augmentation in dog with the bladder acellular matrix graft. J BJU Inter, 85: 362-371.
- Ramesh Kumar B, 1995. Comparative studies on the use of different grafts for experimental cystoplasty in buffalo calves. Ind J Vet Surg, 16: 73.
- Ranganath L and Mahesh V, 2009. Partial cystectomy for urinarybladder carcinoma in dog. Ind J Vet Surg, 30: 137.