



## Subclinical *Clostridium Perfringens* Infection and Marek's Disease in Jordanian Broiler Chickens

F.M. Hayajneh<sup>1</sup>, Abdelqader A<sup>1</sup>, Araj S<sup>2</sup>, Zakaria H<sup>1</sup>, Al-Khazaleh J<sup>3</sup> and Rabie Irshaid<sup>1</sup>

<sup>1</sup>Department of Animal Production, School of Agriculture, University of Jordan, Amman 11942, Jordan

<sup>2</sup>Department of Plant Protection, School of Agriculture, University of Jordan, Amman 11942, Jordan

<sup>3</sup>Department of Nutrition and Food Processing, Faculty of Agricultural Technology, Al-Balqa Applied University, Jordan

\*Corresponding author: [firashope@gmail.com](mailto:firashope@gmail.com)

Article History: 23-211

Received: 17-May-23

Revised: 03-Jun-23

Accepted: 10-Jun-23

### ABSTRACT

Subclinical infections are common in the poultry industry such as *Clostridium perfringens*-induced necrotic enteritis and Marek's disease. This study aims to determine the prevalence of subclinical necrotic enteritis caused by *C. perfringens* and Marek's disease. For *C. Perfringens*, 100 blood samples from 20 intensive poultry broiler farms were collected from June 2020 to September 2020 and analyzed. Upon examining intestinal samples, different degrees of intestinal lesions were noticed, which varied from normal to severe necrosis based on a 0 to 3 scoring system. The blood samples were investigated using an ELISA kit to detect the presence of antibodies against *C. perfringens*. Non-significant difference was noticed between the different farms and different lesion scores. The prevalence of *C. perfringens* in chickens in North Jordan flocks is 14.8%. A significant difference using the chi-square test ( $P=0.004$ ) was noted between infected and non-infected farms. Certain farms showed limited cases (1-2 cases), while others showed higher infections. The prevalence of Marek's disease was investigated in Amman's municipality slaughterhouse and suspected broiler farms located in the Amman region by histopathology and ELISA. For the subclinical MD investigation, a total of 100 chickens from Amman's municipality slaughterhouse were examined where blood samples were tested for antibody presence by ELISA kit together with histopathology, for the clinical MD investigation, 100 chickens from 10 broiler farms were examined by histopathology and ELISA. Blood samples collected from clinical and subclinical cases and tested by ELISA showed a 70% prevalence of Marek's Disease. Of the tissues collected from the slaughterhouse, 30% of the liver samples (average age of 35 days) showed pathological changes. Microscopic examination of tissues showed pleomorphic cell proliferation in the spleen (23%) and liver (20%). It was concluded that clinical and subclinical forms of *C. perfringens* infections and Marek's disease is prevalent in Jordan.

**Key words:** Marek's Disease, *Clostridium Perfringens*, Broilers, Subclinical, Ischaemic Nerve, ELISA.

### INTRODUCTION

*Clostridium perfringens* (*C. perfringens*) cause subclinical necrotic enteritis, usually types A or C and rarely type D. Outbreaks of necrotic enteritis (NE) generally occur at 2 to 6 weeks. Due to the subclinical disease, there is chronic damage to the intestinal mucosa of the chickens, which leads to impaired absorption of nutrients, reduced weight gain, and decreased overall performance. As a result of these factors, subclinical NE causes substantial economic losses to the poultry industry (Kaldhusdal et al. 2016; Emami and Dalloul 2021; Bastamy et al. 2022; He et al. 2022). These losses are anticipated to be 2 billion dollars annually

(Svobodová et al. 2007; Wang et al. 2017; Khalique et al. 2020).

The etiological agent of necrotic enteritis (NE) is *C. perfringens*, which is a disease of chickens (broiler breeders, commercial layers, broilers) and turkeys. Diagnosis of NE is carried out when it results in mortality and at post-mortem mucosal surface of the small intestine appears roughened (Shojadoost et al. 2012). Poultry farmers usually suffer from the greatest economic crunch due to the subclinical form of NE, which results in increased FCR and a lower growth rate (Tang et al. 2022). The clinical form of NE is also sometimes seen in adult and broiler breeder pullets, adult commercial layer and pullets, and turkeys (Hardy et al. 2020).

**Cite This Article as:** Hayajneh FM, Abdelqader A, Araj S, Zakaria H, Al-Khazaleh J and Irshaid R, 2024. Subclinical *Clostridium perfringens* infection and Marek's disease in Jordanian broiler chickens. International Journal of Veterinary Science 13(2): 132-138. <https://doi.org/10.47278/journal.ijvs/2023.060>

Acute and chronic necrotic enteritis cost over \$2 billion annually (Wu et al. 2010). So many factors enhance the occurrence of necrotic enteritis caused by *C. perfringens* in poultry. Nutritional factors and coccidiosis are among the most important determinants of NE occurrence (Moore 2016; Bortoluzzi et al. 2019; Bueno et al. 2023). Among other factors, aflatoxins in the feed could enhance the NE occurrence (Samah et al. 2020; Mehdizadeh et al. 2021). Dietary levels of animal proteins and other cereal contents can affect necrotic enteritis incidents. Cereal dietary components may be more significant because cereals constitute a larger portion of the diet (Iji et al. 2019). Fatalities accompanying NE differ depending on the degree of necrotic enteritis severity (Kaldhusdal et al. 2016; Abd El-Hack et al. 2022; Du et al. 2023).

*C. perfringens* have a significant role in human foodborne disease, as well as in poultry diseases that are not foodborne (Miyamoto et al. 2006). *C. perfringens* enteritis has been reported in most areas of the world and can adversely affect poultry production systems, resulting in necrotic enteritis (Hermans and Morgan 2007). This study aims to investigate the presence of subclinical necrotic enteritis caused by *C. perfringens* infection by testing blood samples of apparently healthy chicken with antibodies against *C. perfringens* and estimating the lesion score caused by this kind of subclinical infection in the northern part of Jordan.

Marek's disease is a common avian infection in chicken flocks worldwide (Birhan et al. 2021). The Herpes virus is an etiological agent which has three serotypes (Stamilla et al. 2020). In chicken, Marek's disease virus (MDV) causes a variety of pathological signs and symptoms in poultry (Lopez et al. 2019; Khan et al. 2021). Marek's disease has three sequential phases; early cytolitic infection, latent infection, and secondary cytolitic infection that is followed by immunosuppression, and tumor development (Islam et al. 2001; Gimeno and Schat 2018).

The visual lesions of Marek's disease were classified into three classes as per histological criteria i) reticulosarcoma or lymphosarcoma-like lesions, ii) lymphogranulomatous type of lesions, and iii) lymphoblastoid lesions (Khan et al. 2021). According to Sun and Cui (2007), once Marek's disease occurred will increase vulnerability to other diseases or may also lead to the death of the bird. Khan et al. (2021) reported the proliferation of infected liver cells that were more prominent in the interlobular connective tissue, particularly around the small blood vessels.

At necropsy, gross lesions of Marek's disease included lymphomas and hepatomegaly, lymphomas in various organs (liver, spleen, kidneys, lungs, ovary, heart, nerves, proventriculus, skin), bursa of Fabricius and thymus atrophy (Metete et al. 2016; Othman and Akilu 2019). Histopathological examination of the affected organs shows polymorphism, fibroblasts, lymphoblasts, lymphocytes, and penetration of tumorous cells arranged in constrained or verbose form, first degeneration then necrosis of liver parenchymal cells, shrinkage of the hepatic ducts and vacuolar degeneration (Witter et al. 2005; Nabinejad et al. 2013, Metete et al. 2016). Time of virus exposure along with the bird's age, genetic factors,

and immune response can influence the clinical expression of Marek's disease and lymphoma presence. Broiler chicks of all ages are vulnerable to Marek's disease, but the occurrence of lymphomas is minimal in old-age birds (Abreu et al. 2016).

Though in advanced stages/clinical form, gross lesions are sufficient for the diagnosis of Marek's disease, however, for subclinical disease, researchers have used various tests for the diagnosis of Marek's disease including ELISA, PCR, real-time PCR, qPCR, histopathology, and immunohistochemistry (Metete et al. 2016; Gall et al. 2018; Tambiev et al. 2021; Zelník 2021; Akhila et al. 2022; Viet Thu et al. 2022). Every technique has its own merits and demerits. Kumar et al. (2016) reported ELISA, particularly dot-ELISA proved to be a specific, rapid, and inexpensive technique for detecting Marek's disease virus.

## MATERIALS AND METHODS

### Animal Ethics

The Scientific Research Council of the University of Jordan approved the experiment's protocols vide number (135/2022). Animals were reared and treated per the EU Directions 2010/63/EU.

### Samples Collection

This study was conducted in northern Jordan. Five birds (age 30 days) were randomly selected from 20 broiler farms. All the farms had no history of vaccination against *C. perfringens*. Blood samples for *C. perfringens* were collected using EDTA tubes, blood was centrifuged, and plasma was kept at -20°C refrigerator until testing; lesion scoring was done after blood collection and sacrificing of the chicken humanly.

For clinically Marek's Disease, poultry farms with some signs such as anorexia, weight loss, diarrhoea, drooping of the limb, and torticollis, a total of 100 alive chickens were randomly selected from 10 broiler farms for histopathology and ELISA examination. Additionally, broiler meat production in Amman's municipality slaughterhouse in Jordan is about 30,000 chicken/day, which was used to study subclinical Marek's Disease. For subclinical Marek's disease investigation, a total of 100 chickens were randomly selected for the collection of blood samples and tissue samples such as liver and spleen, Organs were processed for histopathology and serum harvested from blood was used for ELISA.

Blood samples for Marek's disease were collected before slaughter, via wing veins. About 3.5mL of blood was collected containing ethylenediamine tetra-acetic acid (EDTA). Tissue samples were preserved in 10% formalin and transported to Jordan's university histopathology lab. Tissue specimens were 100 each of liver, spleen, and sciatic plexuses, which were labelled with complete information. Sample size was determined according to Nabinejad (2013).

### ELISA Assay for *C. Perfringens*

The kit used in this experiment was bought from Abbexa Ltd (Cambridge, United Kingdom). This kit is based on sandwich enzyme-linked immune-sorbent assay technology. A 96-well plate has been pre-coated with an

antibody specific to *C. perfringens*. Controls or test samples were added to the appropriate wells and incubated at 37°C for 30 min. Free components are washed away with a wash buffer. HRP conjugated detection reagent is added to the wells. TMB substrate is used to visualize HRP enzymatic reaction. TMB is catalyzed by HRP to produce a blue color product that changes into yellow after adding an acidic stop solution. The intensity of the color yellow is proportional to the *C. perfringens* amount bound on the plate. Spectrophotometrically, OD absorbance is measured at 450 nm in a microplate reader, and the occurrence of *C. perfringens* is determined.

### ELISA Assay for Marek's Disease

The kit used for Marek's disease in this experiment was bought from Shenzhen Lvshiyuan Biotechnology Co., Ltd. The Avian Marek's disease antibody ELISA kit is based on an indirect enzymatic immunoassay (Indirect ELISA). The purified MDV antigen is coated on plates. When testing, added the diluted serum sample, after incubation, if the serum sample contains specific antibodies against MDV, they will bind to the antigen coated on plates. Washed the unbound antibodies and other components. Then added a specific enzyme conjugate, which will combine the antigen-antibody combination on plates. After incubation and washing, discarded the uncombine enzyme conjugate; added the TMB substrate. On appearing a colorimetric reaction, added stop solution, measured OD value by a spectrophotometer (450 nm).

### Lesion Scoring for *Clostridium perfringens* Infection

The small intestine was scored for lesions from 0 to 4, where 0 refers to no necrotic enteritis (healthy manifestation), and 4 refers to a blood-filled intestine with perforation on the epithelial layer. Two experienced personnel performed lesion scoring, which had zero knowledge of the disease being tested in birds (Gharib-Naseri et al. 2019).

### Histopathological Examination

Classical lesions were taken for histopathological preparation. Hematoxylin and Eosin staining was used to demonstrate the developmental stages in the cecum. Tissues sampled were fixed in 10% neutral buffered formalin, sectioned at 4-5µm thicknesses, and stained with hematoxylin-eosin stain (Hayajneh et al. 2020). Tissue samples were processed for histological sections using hematoxylin and eosin staining techniques. Stained slides were examined under a microscope for the description of histopathological lesions (Nabinejad et al. 2013).

### Statistical Analysis

The collected data for *C. perfringens* infection were coded and maintained in an Excel spreadsheet, which was later transported to SPSS version 20 (SPSS Inc. Chicago). The data were analysed by chi square test. The collected data for Marek's disease was analysed by SPSS version 17 (SPSS Inc. Chicago) by repeated measures analysis (RMA). Repeated measures of ANOVA were applied. The treatments and noted variables were dependent on each other. The variations among group means were judged significant at the P value at P<0.05.

## RESULTS AND DISCUSSION

### *Clostridium Perfringens* Infection

The prevalence of *C. perfringens* in chickens in North Jordan flocks was 14.8%. Some farms showed zero prevalence of cases, which could be due to the management system applied in these farms. Comparing the lesion score between infected farms with the non-infected farms and the infected farms with each other revealed significant differences using the chi-square test (Table 1). Individual farms showed limited cases (1-2 farms), while others showed higher infections (Table 2).

**Table 1:** The prevalence of *Clostridium perfringens* in chickens in North Jordan flocks

|                              | Value               | df | P value |
|------------------------------|---------------------|----|---------|
| Pearson Chi-Square           | 15.143 <sup>a</sup> | 4  | 0.004   |
| Likelihood Ratio             | 17.227              | 4  | 0.002   |
| Linear-by-Linear Association | 13.414              | 1  | 0.000   |
| N of Valid Cases             | 100                 |    |         |

<sup>a</sup>5 cells (50.0%) have an expected count of less than 5. The minimum expected count is 1.48. The P-value is considered significant if P<0.05.

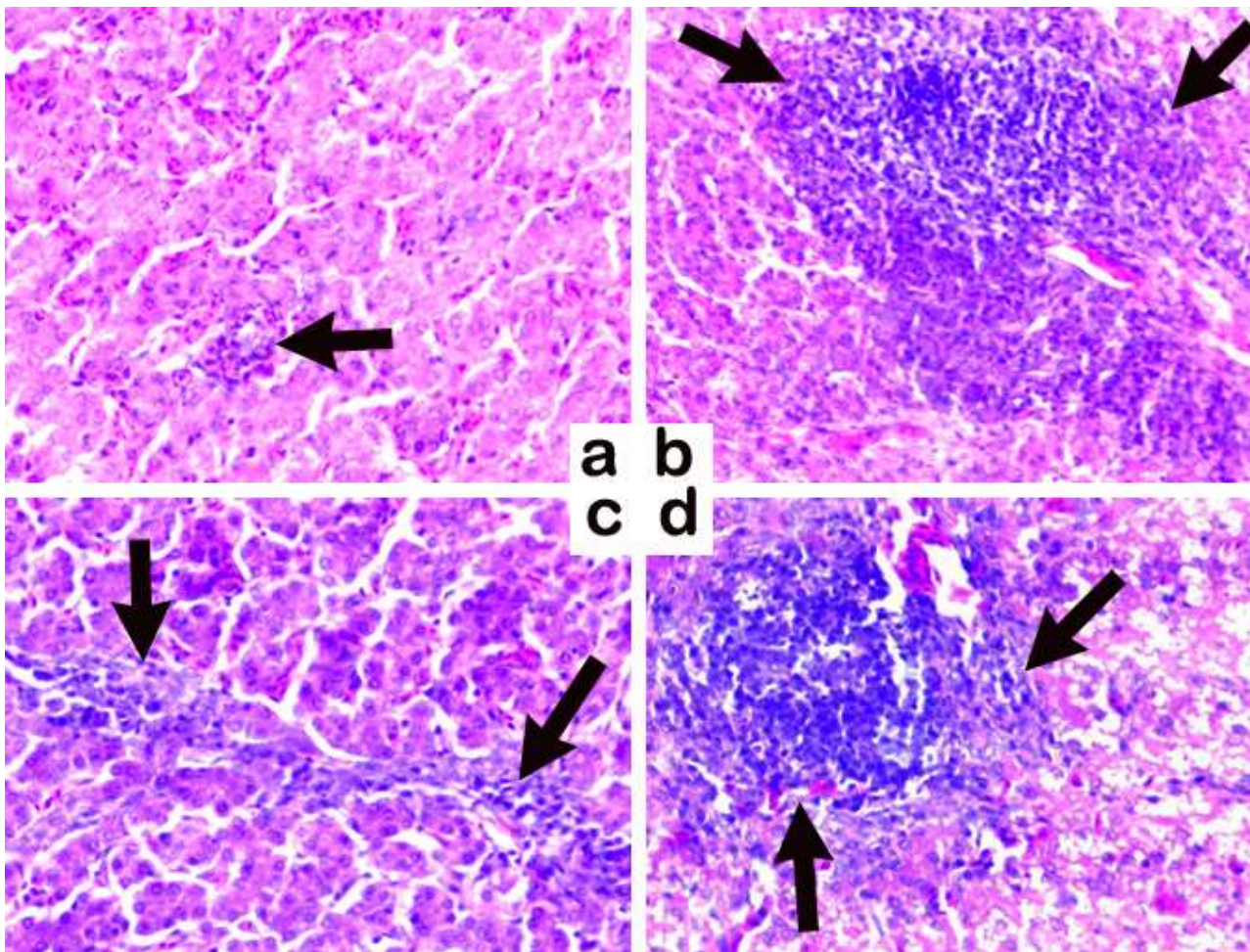
**Table 2:** Gross necrotic enteritis lesions in duodenum, jejunum, and ileum as a result of *Clostridium perfringens* infection in birds

| Lesion score | % birds affected |
|--------------|------------------|
| 0            | 0                |
| 1            | 16               |
| 2            | 16               |
| 3            | 4                |

In Jordan, diagnosis of necrotic enteritis is usually carried out on gross lesions as isolation and identification of the causative agent is a time-consuming and expensive process. The prevalence of *C. Perfringens* of this study are higher than the results of the study conducted by Roussan et al. (2009), where the prevalence of *C. continuum* in broiler flocks in the southern and northern areas of Jordan were 4.7 and 7.1%, respectively, Roussan's results were based on intestinal swabs collected from 170 broiler flocks and tested by PCR, which was statistically significant. The results of this study are truly positive because vaccination against necrotic enteritis is not routinely done in Jordan. According to Gharaibeh et al. (2010), 67 *C. perfringens* isolates were obtained from 155 broiler chicken flocks.

The present study was conducted from July to September (summer months), and the prevalence of subclinical NE was found to be 14.8%. This result agrees with results from Roussan et al. (2009) in Jordan, who investigated the prevalence of *Clostridium colinum*, and Datta et al. (2013) in Canada and (Timbermont et al. 2011) in Germany, who found that this type of infection is more common in the summer season, during the summer times the bedding is wetter than in other seasons.

Application of such ELISA protocol to detect subclinical necrotic enteritis is well-thought-out a supportive tool to investigate the health status of poultry birds and evaluate the effectiveness of anti-clostridial drugs for clostridial infection control (Duff et al. 2019; Posthaus et al. 2020). Using ELISA could result in better diagnosis of NE and then control of subclinical clostridial



**Fig. 1 (a-d):** Microphotographs showing various degenerative changes in the liver collected from Marek’s disease affected chickens. a) Starting of the lesion (arrow) and b-d) visceral form of Marek’s disease in liver showing lymphomatous lesions, mainly consisting of lymphoblasts, and small to medium-sized lymphocytes proliferation in the area (arrows). H and E; X40. H and E; X40.

**Table 3:** Macroscopic lesion scoring system

| Lesion   | Score |
|--|-------|
| No observed lesions                                | 0     |
| Necrosis/ulceration                                | 1     |
| Necrosis Stripes (2 to 3cm long)                   | 2     |
| Diffused necrosis (characteristic for field cases) | 3     |

**Table 4:** Prevalence of clinical and subclinical Marek’s disease in Jordanian poultry

| Clinical Status | Source of blood samples collected |    |                        |    |
|-----------------|-----------------------------------|----|------------------------|----|
|                 | Broiler Farms (n=100)             |    | Slaughterhouse (n=100) |    |
|                 | No.                               | %  | No.                    | %  |
| Clinical        | 100                               | 70 | 100                    | 70 |
| Subclinical     | 100                               | 70 | 100                    | 70 |

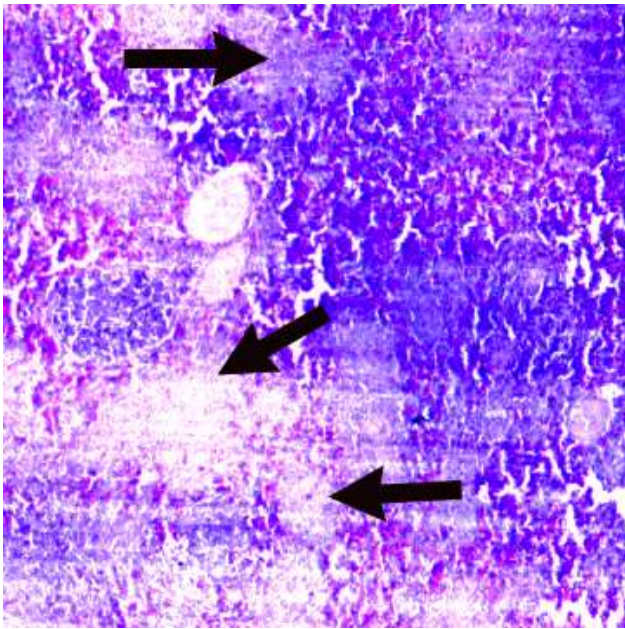
enteritis in broilers as the provision of data by ELISA will help anti-clostridial drugs to control subclinical NE by improving FCR and better weight gain (Edvardsen et al. 2020).

In the past, a subclinical form of NE has increased prevalence, and this might be due to the ban on antimicrobials used as growth promoters in poultry feed. In this form of NE, no obvious clinical signs are observed. There is slow but significant mortality (Du and Guo 2021). There is chronic enteritis that causes substantial mucosal damage that ultimately results in production losses anticipated to poor digestive assimilation and

absorption of nutrients, thus leading to decreased weight gain and increased FCR (Timbermont et al. 2011; Wang et al. 2017). There is a consensus that the subclinical form of the disease is more important than the clinical form because it may persist in broiler flocks without overt clinical manifestation, moreover, because of the large hidden economic costs associated with subclinical necrotic enteritis (Olkowski et al. 2008; Skinner et al. 2010; Kumar et al. 2021).

**Marek’s Disease**

Blood samples tested by ELISA for Marek’s disease showed 70% positive in clinical and subclinical samples, even the same percentage was recorded in blood samples collected from Slaughterhouse (Table 4). A chicken flock with more than two months of age demonstrated seroprevalence of Marek’s disease to be 59.11% (Birhan et al. 2021). Seroconversion and antibody titers were continually increasing until day 84 after immunization (71 days after challenge) was detected only when chickens did not develop Marek’s disease, in contrast, birds developing Marek’s disease having borderline and short-lived antibody titers (Zelník et al. 2004). The high prevalence of Marek’s disease through blood samples could be the result of the good breeder vaccination quality which kept the protection through serum antibodies and the broiler



**Fig 2:** Microphotographs of spleen showing the neoplastic foci formation and depletion of lymphoid follicles from the germinal centers (arrows). H and E; X40.

flocks, the use of recombinant vaccines against other viral diseases in Jordan, that depend on Marek's disease virus can also explain the high prevalence of Marek's disease antibodies in the samples tested (Porter 2021).

In the present study, of the tissues collected from slaughterhouses from Marek's disease-affected birds, 30% of the liver samples (average age of 35 days) showed pathological changes. Microscopic examination of tissues showed pleomorphic cell proliferation in spleens (23%) and livers (20%). Histopathologically, the liver (Fig. 1) and spleen (Fig. 2) showed neoplastic cells and pleomorphic neoplastic lymphoreticular cells. The lesions in Fig. 1 are comparable with Marek's disease and similar to those described by Fodor et al. (2009). Vieira-Pinto et al. (2003) reported that histopathology could be used to confirm the presence of Marek's disease. Marek's disease infection in vaccinated birds could be the result of poor biosecurity (Fossum et al. 2009; Birhane and Fesseha 2020; Akhtar et al. 2023).

Vaccination failure, the existence of a pathogenic Marek's disease virus strain, or low genetic resistance to Marek's disease, seem to be risk factors (Buscaglia et al. 2004). Zelník et al. (2004) reported the incidence of Marek's disease in vaccinated birds. The gross and microscopic lesions observed in the current study are in agreement with Marek's disease lesions reported in the published literature (Othman and Aklilu 2019).

In the present study, in some sections, lymphomatous lesions were found (Fig. 1) which were mainly elongated and small to medium-sized lymphoblasts and lymphocytes. Tumor compositions are similar between organs, but sometimes the involvement may vary (Stamilla et al. 2020; Khan et al. 2021). Wen et al. (2018) reported the existence of Marek's disease virus in the nucleus of lymphoid tumor cells in the liver with the presence of Meg Protein. This protein is believed a major factor that may lead to the development of tumors (Lee et al. 2000).

## Conclusion

Necrotic enteritis, subclinical in nature, caused by *Clostridium perfringens*, is substantially prevalent in Jordan. These results provide evidence that enteritis caused by *C. perfringens* should not be overlooked and indicate that intervention strategies should be done; a future study to determine the weight loss and economic losses caused by such kinds of enteritis, with or without the presence of other causes of enteritis such as coccidiosis should be made. Vaccination against Marek's disease is not routinely done in broiler flocks in Jordan, this study proves the presence of subclinical disease in broiler flocks in Jordan, clinical signs are not usually seen, for this reason, it is recommended to either add measures to eradicate the disease or vaccinate broiler flocks against this disease and to reconsider vaccination of broiler breeder flocks against this disease. Changing the chick's genetic strains, vaccination, and better biosecurity levels are much needed to eliminate Marek's disease virus.

## Conflict of Interest

The authors declare no conflict of interest.

## Acknowledgment

The authors want to thank the University of Jordan for the financial support of this research project.

## Data Availability

All data generated or analysed during this study are included in this published article.

## REFERENCES

- Abd El-Hack ME, El-Saadony MT, Elbestawy AR, El-Shall NA, Saad AM, Salem HM, El-Tahan AM, Khafaga AF, Taha AE, AbuQamar SF and El-Tarabily KA, 2022. Necrotic enteritis in broiler chickens: disease characteristics and prevention using organic antibiotic alternatives - a comprehensive review. *Poultry Science* 101(2): 101590. <https://doi.org/10.1016/j.psj.2021.101590>
- Abreu DLC, Santos FF, José, Tortelly R, Nascimento ER and Pereira VLA, 2016. Pathological Aspects of a Subclinical Marek's Disease Case in Free-Range Chickens. *Revista Brasileira de Ciencia Avicola* 8(1): 197-200. <https://doi.org/10.1590/18069061-2015-0001>
- Akhila N, Samatha V, Devi VR, Chowdary SR, Yashaswi Y and Padmini V, 2022. Pathological and molecular diagnosis of Marek's Disease in desi birds. *The Pharma Innovation Journal* SP-11(7): 3995-3999.
- Akhtar T, Shahid S, Asghar A, Naeem MI, Aziz S and Ameer T, 2023. Utilisation of herbal bullets against Newcastle disease in poultry sector of Asia and Africa (2012-2022). *International Journal of Agriculture and Biosciences* 12(1): 56-65. <https://doi.org/10.47278/journal.ijab/2023.044>
- Bastamy M, Raheel I, Ellakany H, Samir A, Hamoud M, Khalifa RA, Ibrahim S, El Rahman SA and Orabi A, 2022. Insight of prevalence, toxin typing and antimicrobial susceptibility of Egyptian *Clostridium perfringens* isolates recovered from broiler, layer and breeder chicken flocks. *International Journal of Veterinary Science* 11(1): 110-116. <https://doi.org/10.47278/journal.ijvs/2021.080>
- Birhan M, Berhane N, Bitew M, Gelaye E, Getachew B, Zemene A, Birie K, Temesgen W and Abayneh T, 2021. Sero-Epidemiology of Marek's Disease Virus on Local and Exotic Chickens in Northwest Ethiopia, *Journal of World's*

- Poultry Research 11(1): 53-63. <https://dx.doi.org/10.36380/jwpr.2021.8>
- Birhane N and Fesseha H, 2020. Vaccine failure in poultry production and its control methods: A review. Biomedical Journal of Scientific and Technical Research 29(4): 22588-22596. <https://doi.org/10.26717/BJSTR.2020.29.004827>
- Bortoluzzi C, Vieira BS, Hofacre C and Applegate TJ, 2019. Effect of different challenge models to induce necrotic enteritis on the growth performance and intestinal microbiota of broiler chickens. Poult Science 98(7): 2800-2812. <https://doi.org/10.3382/ps/pez084>
- Bueno I, Rieke I, Hwang H, Smith E, Nault A, Johnson TJ and Singer RS, 2023. Efficacy of antibiotic and non-antibiotic interventions in preventing and treating necrotic enteritis in broiler chickens: A Systematic Review. Avian Diseases 67(1): 20–32. <https://doi.org/10.1637/aviandiseases-D-22-00069>
- Buscaglia C, Nervi P and Risso M, 2004. Characterization of four very virulent Argentinian strains of Marek's disease virus and the influence of one of those isolates on synergism between Marek's disease vaccine viruses. Avian Pathology 33 (2): 190-195. <https://doi.org/10.1080/03079450310001652103>. PMID: 15276986.
- Datta S, Rakha NK, Narang G and Mahajan K, 2013. Epidemiology of enteritis in broiler chickens in the state of Haryana and its association with different meteorological parameters. Haryana Veterinarian 52: 22-25.
- Du E and Guo Y, 2021. Dietary supplementation of essential oils and lysozyme reduces mortality and improves intestinal integrity of broiler chickens with necrotic enteritis. Animal Science Journal 92(1): e13499. <https://doi.org/10.1111/asj.13499>
- Du XX, Gul ST, Ahmad L, Hussain R and Khan A, 2023. Fowl typhoid: Present scenario, diagnosis, prevention, and control measures. International Journal of Agriculture and Biosciences 12(3): 172-179. <https://doi.org/10.47278/journal.ijab/2023.061>
- Duff AF, Vuong CN, Searer KL, Briggs WN, Wilson KM, Hargis BM, Berghman LR and Bielke LR, 2019. Preliminary studies on development of a novel subunit vaccine targeting *Clostridium perfringens* mucolytic enzymes for the control of necrotic enteritis in broilers. Poultry Science 98(12): 6319–6325. <https://doi.org/10.3382/ps/pez448>
- Edvardson DH, Sanson G, Løvland A and Kaldhusdal M, 2020. Effect of feed additives as alternatives to in-feed antimicrobials on production performance and intestinal *Clostridium perfringens* counts in broiler chickens. Animals 10(2): 240. <https://doi.org/10.3390/ani10020240>
- Emami NK and Dalloul RA, 2021. Centennial Review: Recent developments in host-pathogen interactions during necrotic enteritis in poultry. Poultry Science 100(9): 101330. <https://doi.org/10.1016/j.psj.2021.101330>
- Fodor I, Coman M and Cătană N, 2009. An outbreak of Marek's disease in broiler chickens: epidemiological, clinical and anatomopathological aspects. Lucrari Stiintifice Medicina Veterinaria 42(1): 224-229
- Fossum O, Jansson DS, Etterlin PE and Vågsholm I, 2009. Causes of mortality in laying hens of different housing systems in 2001 to 2004. Acta Veterinaria Scandinavia 51 (3): 1-9. <https://doi.org/10.1186/1751-0147-51-3>
- Gall S, Körösi L, Cortes AL, Delvecchio A, Prandini F, Mitsch P and Gimeno IM, 2018. Use of real-time PCR to rule out Marek's disease in the diagnosis of peripheral neuropathy. Avian Pathology 47(4): 427–433. <https://doi.org/10.1080/03079457.2018.1473555>
- Gharaibeh S, Al Rifai R and Al-Majali A, 2010. Molecular typing and antimicrobial susceptibility of *Clostridium perfringens* from broiler chickens. Anaerobe 16: 586-589. <https://doi.org/10.1016/j.anaerobe.2010.10.004>
- Gharib-Naseri K, Kheravii SK, Keerqin C, Morgan N, Swick RA, Choct M and Wu SB, 2019. Two different *Clostridium perfringens* strains produce different levels of necrotic enteritis in broiler chickens. Poultry Science 98: 6422-6432. <https://doi.org/10.3382/ps/pez480>
- Gimeno IM and Schat KA, 2018. Virus-induced immunosuppression in chickens. Avian Diseases 62(3): 272–285. <https://doi.org/10.1637/11841-041318-Review.1>
- Hardy SP, Benestad SL, Hamnes IS, Moldal T, David B, Barta JR, Reperant JM and Kaldhusdal M, 2020. Developing an experimental necrotic enteritis model in turkeys - the impact of *Clostridium perfringens*, *Eimeria meleagridis* and host age on frequency of severe intestinal lesions. BMC Veterinary Research 16: 63. <https://doi.org/10.1186/s12917-020-2270-5>
- Hayajneh FMF, Abdelqader A, Alnimer MA, Abedal-Majed MA and Al-Khazaleh, J, 2020. The role of high-grade Bentonite powder in coccidiosis and its effects on feed conversion ratio and blood parameters in broiler chicken. Polish Journal of Veterinary Sciences 23 (1): 97–107. <https://doi.org/10.24425/pjvs.2020.132753>
- He W, Goes EC, Wakaruk J, Barreda DR and Korver DR, 2022. a poultry subclinical necrotic enteritis disease model based on natural *Clostridium perfringens* uptake. Frontiers in Physiology 13: 788592. <https://doi.org/10.3389/fphys.2022.788592>
- Hermans PG and Morgan KL, 2007. Prevalence and associated risk factors of necrotic enteritis on broiler farms in the United Kingdom; a cross-sectional survey. Avian Pathology 36: 43–51. <https://doi.org/10.1080/03079450601109991>
- Iji P, Omede A, Abdallah M and Ahiwe E, 2019. The role of specific cereal grain dietary components in poultry gut function. In: Rieke SC (ed), Improving gut health in poultry. 1st Ed, Burleigh Dodds Science Publishing
- Islam AF, SW Walkden-Brown, Burgess S K and Groves PJ, 2001. Marek's disease in broiler chickens: effect of route of infection and herpesvirus of turkey-vaccination status on detection of virus from blood or spleen by polymerase chain reaction, and on weights of birds, bursa and spleen. Avian Pathology 30: 621–628. <https://doi.org/10.1080/03079450120092116>
- Kaldhusdal M, Sylvie L, Benestad and Løvland A, 2016. Epidemiologic aspects of necrotic enteritis in broiler chickens – disease occurrence and production performance. Avian Pathology 45: 271-274. <https://doi.org/10.1080/03079457.2016.1163521>
- Khalique A, Zeng D and Shoaib M, 2020. Probiotics mitigating subclinical necrotic enteritis (SNE) as potential alternatives to antibiotics in poultry. AMB Express 10(50). <https://doi.org/10.1186/s13568-020-00989-6>
- Khan A, Akram M, Noor-un-Nisa, Khatoun N, Waheed S and Khan A, 2021. Histological study of Broiler chicken liver infected with Marek's Disease (MDV). Pure and Applied Biology 10 (4): 1028-1032. <http://dx.doi.org/10.19045/bspab.2021.100107>
- Kumar A, Kheravii SK, Li L and Wu SB, 2021. Monoglyceride blend reduces mortality, improves nutrient digestibility, and intestinal health in broilers subjected to clinical necrotic enteritis challenge. Animals (Basel) 11(5): 1432. <https://doi.org/10.3390/ani11051432>
- Kumar MA, Barathidasan R, Palanivelu M, Singh SD, Wani MY, Malik YS, Singh R and Dhama K, 2016. A novel recombinant Meq protein-based dot-ELISA for rapid and confirmatory diagnosis of Marek's disease induced lymphoma in poultry. Journal of Virological Methods 236: 271–280. <https://doi.org/10.1016/j.jviromet.2016.08.007>
- Lee S, Takagi M, Ohashi K, Sugimoto C and Onuma M, 2000. Difference in the meg gene between oncogenic and

- attenuated strain of Marek's disease virus serotype I. *Journal of Veterinary Science* 62: 287- 292. <https://doi.org/10.1292/jvms.62.287>
- Lopez S, David Villar A and Gutiérrez JJC, 2019. Challenges in the diagnosis and control of Marek's disease virus in Colombia. *Revista MVZ Cordoba* 24(1):7157-7165. <https://doi.org/10.21897/rmvz.1413>
- Mehdizadeh Gohari I, A Navarro M, Li J, Shrestha A, Uzal F and A McClane B, 2021. Pathogenicity and virulence of *Clostridium perfringens*. *Virulence* 12(1): 723-753. <https://doi.org/10.1080/21505594.2021.1886777>
- Mete A, Gharpure R, Pitesky ME, Famini D, Sverlow K and Dunn J, 2016. Marek's disease in backyard chickens, a study of pathologic findings and viral loads in tumorous and nontumorous birds. *Avian Diseases* 60(4): 826-836. <https://doi.org/10.1637/11458-062216-Reg>
- Miyamoto K, Fisher DJ, Li J, Sayeed S, Akimoto S and McClane BA, 2006. Complete sequencing and diversity analysis of the enterotoxin-encoding plasmids in *Clostridium perfringens* type A non-food-borne human gastrointestinal disease isolates. *Journal of Bacteriology* 188: 1585-1598. <https://doi.org/10.1128/JB.188.4.1585-1598.2006>
- Moore RJ, 2016. Necrotic enteritis predisposing factors in broiler chickens. *Avian Pathology* 45(3): 275-281. <https://doi.org/10.1080/03079457.2016.1150587>
- Nabinejad A, 2013. Study on subclinical and clinical Marek's disease (MD) in the broiler chickens using histopathology. *International journal of Advanced Biological and Biomedical Research* 1(8): 795-801.
- Olkowski, AA, Wojnarowicz C, Chirino-Trejo M, Laarveld B and Sawicki G, 2008. Subclinical necrotic enteritis in broiler chickens: novel etiological consideration based on ultra-structural and molecular changes in the intestinal tissue. *Research in Veterinary Science* 85: 543-553. <https://doi.org/10.1016/j.rvsc.2008.02.007>
- Othman I and Aklilu E, 2019. Marek's disease herpesvirus serotype 1 in broiler breeder and layer chickens in Malaysia. *Veterinary World* 12(3): 472-476. <https://doi.org/10.14202/vetworld.2019.472-476>
- Porter R, 2021. Vaccination of poultry. In: Greenacre CB and Morishita TY (eds), *Backyard Poultry Medicine and Surgery: A Guide for Veterinary Practitioners*. 2<sup>nd</sup> Ed, Wiley Library. <https://doi.org/10.1002/9781119511816.ch30>
- Posthaus H, Kittl S, Tarek B and Bruggisser J, 2020. *Clostridium perfringens* type C necrotic enteritis in pigs: diagnosis, pathogenesis, and prevention. *Journal of Veterinary Diagnostic Investigation* 32(2): 203-212. <https://doi.org/10.1177/1040638719900180>
- Roussan DA, Al Rifai RH, Khawaldeh GY and Totanji WS, 2009. Flock-level prevalence of *Clostridium colinum* in broiler flocks with digestive disease in Jordan by polymerase chain reaction. *Poultry Science* 88: 1639-1642. <https://doi.org/10.3382/ps.2009-00042>
- Samah E; Nayera MEA, Fatma A, Hala NTH and Hamed RI, 2020. Prevention of necrotic enteritis in broiler chickens by prebiotics and probiotics VS control by antibiotics, in vivo study. *Alexandria Journal for Veterinary Sciences* 64(1): 143-153.
- Shojadoost B, Vince AR and Prescott JF, 2012. The successful experimental induction of necrotic enteritis in chickens by *Clostridium perfringens*: a critical review. *Veterinary Research* 43: 74. <https://doi.org/10.1186/1297-9716-43-74>
- Skinner JT, Bauer S, Young V, Pauling G and Wilson J, 2010. An economic analysis of the impact of subclinical (mild) necrotic enteritis in broiler chickens. *Avian Diseases* 54: 1237-1240. <https://doi.org/10.1637/9399-052110-Reg.1>
- Stamilla A, Messina A, Condorelli L, Licitra F, Antoci F, Lanza M, Ruggero Loria G, Cascone G and Puleio R. 2020. Morphological and Immunohistochemical Examination of Lymphoproliferative Lesions Caused by Marek's Disease Virus in Breeder Chickens. *Animals* 10: 1280. <https://doi.org/10.3390/ani10081280>
- Sun SH and Cui ZZ, 2007. Epidemiological and pathological studies subgroup J avian leukosis virus infections in Chinese local "yellow" chickens. *Avian Pathology* 36: 221-226. <https://doi.org/10.1080/03079450701332345>
- Svobodová I, Steinhäuserová I and Nebola M, 2007. Incidence of *Clostridium perfringens* in Broiler Chickens in the Czech Republic. *Acta Veterinaria Brno* 76: S25-S30. <https://doi.org/10.2754/avb200776S8S025>
- Tambiev T, Tazayan A, Fedorov V, Gak Y, Derezina T, and Avetisyan D, 2021. Features of the Manifestation of Marek's Disease in Poultry Farms of the Rostov Region, Russian Federation. *KnE Life Sciences* 6(3): 601-610. <https://doi.org/10.18502/cls.v0i0.8996>
- Tang Y, Zhang X, Wang Y, Guo Y, Zhu P, Li G, Zhang J, Ma Q and Zhao L, 2022. Dietary ellagic acid ameliorated *Clostridium perfringens*-induced subclinical necrotic enteritis in broilers via regulating inflammation and cecal microbiota. *Journal of Animal Science and Biotechnology* 13(1): 47. <https://doi.org/10.1186/s40104-022-00694-3>
- Timbermont L, Haesebrouck F, Ducatelle R and Van Immerseel F, 2011. Necrotic enteritis in broilers: an update on the pathogenesis. *Avian Pathology* 40: 341-347.
- Vieira-Pinto M, Mateus T, Seixas F, Fontes MC and Martins CO. 2003. papel da Inspeção sanitária postmortem em matadouro na detecção de lesões e processos patológicos em aves. Quatro casos de lesões compatíveis com a doença de Marek em carcaças de aves rejeitadas. *Revista Portuguesa de Ciências Veterinárias* 98(547): 145-148. <https://doi.org/10.31416/rsdv.v8i3.34>
- Viet Thu HT, Trang HN, Phuoc Chien NT, Ngu NT and Hien ND, 2022. Occurrence of Marek's disease in backyard chicken flocks in Vietnam. *Avian Diseases* 66(2): 230-236. <https://doi.org/10.1637/aviandiseases-D-22-00009>
- Wang H, Ni X, Qing X, Liu L, Lai J, Khaliq A, Li G, Pan K, Jing B and Zeng D, 2017. Probiotic enhanced intestinal immunity in broilers against subclinical necrotic enteritis. *Frontiers in Immunology* 8: 1592. <https://doi.org/10.3389/fimmu.2017.0159>
- Wen Y, Huang Qi, Yang C, Pan L and Wang G, 2018. Characterizing the histopathology of natural co-infection with Marek's disease virus and subgroup J avian leukosis virus in egg-laying hen. *Journal of Avian Pathology* 47: 83-89. <https://doi.org/10.1080/03079457.2017.1375079>
- Witter RL, Calnek BW, Buscaglia C, Gimeno IM and Schat KA, 2005. Classification of Marek's disease viruses according to pathotype: philosophy and methodology. *Avian Pathology* 34(2): 75-90.
- Wu SB, Rodgers N and Choct M, 2010. Optimized necrotic enteritis model producing clinical and subclinical infection of *Clostridium perfringens* in broiler chickens. *Avian Diseases* 54: 1058-1065. <https://doi.org/10.1637/9338-032910-Reg.1>
- Zelník V, 2021. Use of nucleic acids amplification methods in Marek's disease diagnosis and pathogenesis studies. *Acta Virologica* 65(1): 27-32. [https://doi.org/10.4149/av\\_2021\\_108](https://doi.org/10.4149/av_2021_108)
- Zelník V, Harlin O, Fehler F, Kaspers B K, Gobel TW, Nair VK and Osterrieder N, 2004. An enzyme-linked immunosorbent assay (ELISA) for detection of Marek's disease virus-specific antibodies and its application in an experimental vaccine trial. *Journal of Veterinary Medicine B51: 61-67.* <https://doi.org/10.1111/j.14390450.2004.00728.x>