



Fundamentals of Diagnostic Ultrasound in Dromedary Camel Medicine

Mohamed Tharwat

Department of Veterinary Medicine, College of Agriculture and Veterinary Medicine, Qassim University, P.O. Box 6622, Buraidah, 51452, Saudi Arabia

*Corresponding author: atieh@qu.edu.sa

Article History: 23-204

Received: 10-May-23

Revised: 01-Jun-23

Accepted: 04-Jun-23

ABSTRACT

This review focuses on the principles of diagnostic ultrasound in dromedary camel medicine. The first section of the review concentrates on scanning of the abdominal cavity of both sick and sound ones including sonography of the gastrointestinal tract and physical feedbacks followed by the implementation in different belly diseases. The second part of the review will focus on hepatic scanning of both sound and unhealthy camels including hepatic sonography in camels and natural results, evaluation of the liver echotexture, size and positioning and evaluation of the hepatic veins. It will be also followed by the application of ultrasound in some hepatic disorders in camels. The third section of this review will discuss renal imaging in sound and unhealthy camels including renal sonography and detected results. Parallel, it will be followed by application in different renal disorders. The last section of this article will emphasize thoracic imaging of both sound and unhealthy ones including procedures of pulmonary ultrasonography and findings in healthy camels and echocardiographic protocol and findings. Using sonography in detecting thoracic disorders such as myocardial degeneration, pneumonia, pulmonary abscessation, pulmonary emphysema, pleural effusion, pleurisy and pleuropneumonia will be followed.

Key words: Animals, Animal health, Diagnostic imaging, Diseases, Pathophysiology

INTRODUCTION

In humans, ultrasound has been developed extensively during the past seventy years and it currently being implemented in general practice (Andersen et al. 2019; Díaz-Gómez et al. 2021; Nielsen et al. 2021). In veterinary medicine, diagnostic ultrasound is used during the past two decades on a large scale as a safe, fast and non-invasive methodology for the early detection, diagnosis and prognosis of different animal diseases (Crilly 2022; Sary et al. 2022; Braun et al. 2023; Turner et al. 2023). The technique is used also for guidance during treatment procedures and also for biopsy of tissue specimens for confirmatory diagnosis by histopathological examination (Shimizu et al. 2021; Hawkins et al. 2022; Scheemaeker et al. 2023).

The advantages of sonography in veterinary field are abundant. The procedure supplements the physical as well as lab testing through supplying extra data on different diseases of the abdomen for early verification of these disorders. Current review is designed to show the findings of diagnostic ultrasound in sound camels and in those suffering from different thoracoabdominal affections. Sonography is frequently reported to be noninvasive and

harmless methodology for the patient, the worker and thus permitting to be carried out in any site. It is therefore frequently used in un-sedated individuals for frequent testing for monitoring, making serial examinations to monitor the advancement of the case, comply to therapy. In camel medicine, ultrasonography has been used extensively in camel medicine during the last years (El-Shafaey et al. 2020; Tharwat, 2020a, b, c; Tharwat, 2021). It helps the veterinarian to get allows the clinician to obtain immediate data concerning different systems either in the sound or ill conditions. Following, ultrasound findings of various body systems in healthy and diseased camels will be discussed in detail, especially on findings of the cardiovascular, respiratory, digestive, urinary and hepatic systems and various affections affecting these systems.

Abdominal sonography in sound and unhealthy camels

Several reports are published describing the methodology of abdominal ultrasonographic imaging in both sound and unhealthy camels (Tharwat et al. 2012a, b,c,d; Tharwat, 2013a; Tharwat et al. 2013; Tharwat and Al-Sobayil 2016a; Tharwat et al. 2018a; Tharwat 2019; Sadan et al. 2020; Tharwat 2020a). Following, some abdominal diseases will be evaluated by ultrasonography.

Gastrointestinal Disorders

Blockage of the Intestines

Blockage of either small or large intestines in camels is usually caused by balls made of wool and by large numbers of parasites. In camels, intestinal obstruction may be caused by wool balls, massive intestinal parasitic infestations and odd structures. The condition may occur through external pressure by large node, abscess formation and tumors. Overdistension of the large intestine by undigested food in old camels is another etiology of bowel blockage in camels (Tharwat et al. 2012b). When scanning the abdomen of a camel with blockage of the abdomen, different findings may be acquired. It includes loop dilations, decreased intestinal movement and echogenic balls. It was reported recently that diagnostic ultrasound can also be used for correct localization, prognosis and deciding treatment option in camels with foreign bodies swallowing syndrome (Sadan et al. 2020). Small intestinal twisting occurs in both young and adult camels and may include the large intestine. Consequences of intestinal twisting include loop dilatation, distension of the abdomen, engorgement of the blood vessels and finally collapse in uncorrected cases. Blockage of the intestines is suspected if intestines are dilated, motility is decreased or lost at all, and in severe cases, hypoechogenic material and tags of fibrin are seen among loops. Telescoping may also occur in some diseased camels where a small portion enters in a large portion of the intestines (Tharwat et al. 2012b).

Abdominal Fluids and Chronic Peritonitis

Effusions in the abdomen are frequent finding in dromedaries. It may be caused by *Trypanosoma evansi* infection, heart failure, decreased blood proteins, diseases of the liver and kidneys, inflammation of the peritoneum and widespread tumors (Tharwat, 2013a; Jilo et al. 2017; Tharwat et al. 2018a; Tharwat 2019). Scanning of the abdomen in camels with *Trypanosoma evansi* infection reveals the accumulation of hypoechoic fluid; sometimes massive where the viscera are natant. Differential diagnosis includes heart failure, liver and kidney diseases and long-standing parasitic infestation (Tharwat et al. 2012b; Tharwat 2013a). Sonographic findings of the abdomen in camels with inflammation of the peritoneal membranes includes the presence of tags of fibrin appearing sonographically hyperechoic within a hyperechoic abdominal fluid (Tharwat 2019) (Fig. 1).

Abscessations of the Abdominal and Pelvic Cavities

Abscess formation within the abdominal and pelvic cavities may be detected as a result of different infections. Clinical presentations may be similar to that of intestinal blockage and loss of urination and defecation. By sonography, the condition can easily be verified where a mass of different sizes could be imaged within the abdominal or pelvic cavity. Centesis of a pyogenic material under ultrasound guidance usually confirm the condition. Distension of the urinary bladder usually follows if the abscess formation exists within the pelvis and compressing the bladder opening; in such case the bladder is imaged containing hyperechoic deposits. The ureter may be also compressed by the mass causing urine accumulation in one-side kidney (Tharwat and Al-Sobayil 2016a).

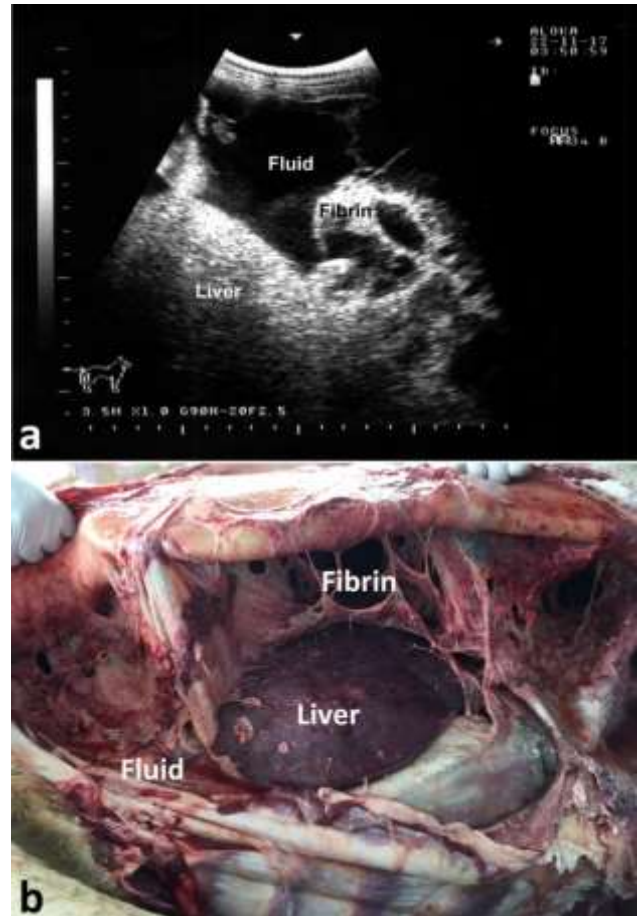


Fig. 1: Chronic peritonitis in a female camel. Fibrin and hyperechoic fluid are imaged within the peritoneal exudation (a). Image (b) shows necropsy findings where massive fibrin network and adhesion of the viscera together and to the abdominal wall together with serosanguineous abdominal exudate were detected.

Paratuberculosis (Johne's disease; JD) and Neoplasia

In camels with JD, abdominal sonography shows an increased thickness as well as wrinkling of the intestinal mucosa. Gross enlargement of the mesenteric nodes is the remarkable finding (Wernery and Kaaden 2002). The capsule of the enlarged node may be hyperechoic or anechoic and the inclusions may be hyperechoic, anechoic or mixed nature. Among the loops of intestines, hyperechogenic tissue with pockets of fluids may also be scanned. Bright liver picture and effusions of the pericardium and pleura are additional findings (Tharwat et al. 2012d). Different tumors were reported in dromedaries (Tharwat et al. 2017; Ali et al. 2018; Al-Sobayil et al. 2018; Tharwat et al. 2018a). It must be stressed that ultrasonography can be used as a screening technique for early detection of infected camels by paratuberculosis. However, laboratory confirmation remains the final diagnosis. Standard methods for the diagnosis of paratuberculosis in camels are culture method and molecular diagnosis by polymerase chain reaction (Salem et al. 2019).

Hepatic Sonography in Sound and Unhealthy Camels

Liver diseases are frequently reported in dromedaries (Fowler 2010). Various liver diseases are detected only incidentally post-mortem as clinical presentations are not indicative and also laboratory data may be unaided, and hence subsidiary techniques may be wanted (Tharwat et al.

2012e,f; Tharwat 2020b). Liver parenchyma in camel are composed of abundant, moderate echoes regularly spread throughout the hepatic tissue. The hepatic blood vessels included portal, hepatic and caudal vena cava are imaged within the parenchyma (Tharwat et al. 2012e).

Liver Disorders

A number of diseases can affect camel liver but infectious diseases, toxic substances, fatty liver, parasitic hepatitis and tumors are considered as the most common etiologies (Belina et al. 2015). In addition, in abattoir study carried out on 822 slaughtered camels, liver abscesses were found at a percent of 13.5%. Laboratory culture showed that *Staphylococcus* spp. (41.1%), *Corynebacterium* spp. (17.9%) and *Streptococcus* spp. (13.3%) were the most frequently identified bacteria involved in liver abscesses of the camels (Aljameel et al. 2014).

Ultrasonography of Fatty Liver, Hepatic Abscessations, Bile Duct Calcification and Abnormalities of the Caudal Vena Cava

Sonographically, the liver tissue is imaged brighter in camels with fatty liver versus healthy liver. The disorder may be localized or spread throughout the liver. In advanced and untreated cases, the area of the liver close to the right abdomen is echogenic while the far areas are hypoechogenic or even anechoic (Tharwat 2020b). Imaging of a hepatic abscess revealed a hypo or hyperechogenic area based on the time of scanning in the early or late phase Bile duct calcification appear hyperechogenic and are manifested by sharp echoes together with distal black shade (Fig. 2). The caudal vena cava (CVC), looks triangular; it may be imaged oval in conditions causing generalized blood congestion such as heart failure, CVC vegetations, and thoracic pressure on CVC by a mass (Tharwat et al. 2012c).

Sonography of the Kidneys in Sound and Unhealthy Camels

Sonography of the right kidney is usually performed in camels at right paralumbar fossa and at 10th to 11th intercostal spaces. On the left side, the left kidney is scanned at the caudal region of the left paralumbar fossa; it can also be accessed transrectally (Tharwat et al. 2012e). It is possible to differentiate Sonographically among the cortex, medulla and renal pelvis; the cortex is hyperechogenic versus medulla and the renal pelvis is echogenic and could be easily distinguished from other renal parts (Tharwat et al. 2012e).

Kidney Disorders

Disorders of kidney are numerous in camels. In an abattoir survey, kidney lesions included medullary hyperemia, renal capsular pigmentation, cortical and medullary discoloration, subcapsular calcification, nephrolithiasis, hydatidosis, hemorrhages in renal pelvis. In addition, acute tubular necrosis, capsular melanosis, caseous necrosis, chronic interstitial nephritis, medullary hyperemia, calcification and hydatid cyst were confirmed histologically (Kojouri et al. 2014). Sonographically, some disorders were reported to be imaged such as urolithiasis. A urinary calculi are imaged in camels as an enhanced echo with distal black shadow

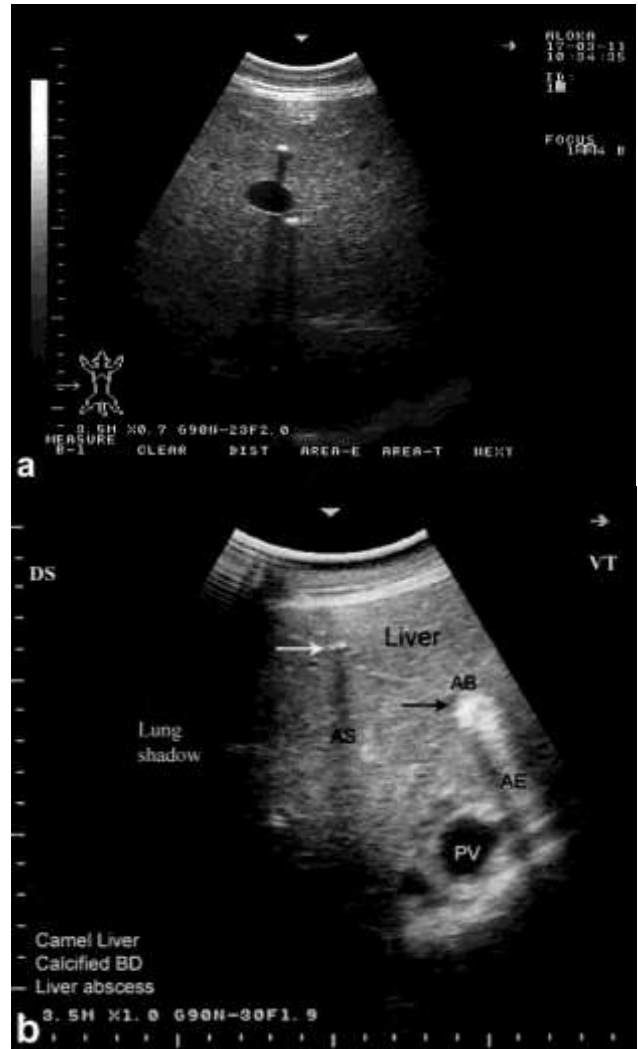

Fig. 2: Calcified bile ducts and hepatic abscess detected by ultrasonography in 2 apparent healthy camels. Intense echoes are imaged accompanied by a distal acoustic shadow (a, b). AS, acoustic shadowing; AB, abscess; PV, portal vein. Arrow in image b points to the calcified bile duct.

(Tharwat 2020c; Tharwat 2021) (Fig. 3). Distended urinary bladder and urine accumulation within the left renal pelvis is detected transrectally in case of hydronephrosis of both sides. The conditions of hydronephrosis or pyelonephritis may be also verified transcutaneously at the right or left paralumbar fossae (Tharwat et al. 2018b,c). Renal tumors may be also evaluated antemortem in camels. Rectal sonography of a right kidney tumor showed a misshaped and hypoechogenic mass that was situated caudally. On the other hand, the left kidney imaged normal (Tharwat et al. 2017).

Sonography of the Thorax

Scanning of the lungs and heart in camels has been reported (Tharwat et al. 2012f; Tharwat 2013b). Because of the air contents, the pulmonary parenchyma could not be visualized in healthy dromedaries. The central and visceral pleurae appeared as a hyperechogenic line.

Artifacts of parallel reverberations as lines of different echoes are imaged; it became attenuated deeply (Tharwat 2013b). Two-dimensional echocardiography has also been reported in camels on the right and left sides of the thorax (Tharwat et al. 2012f).

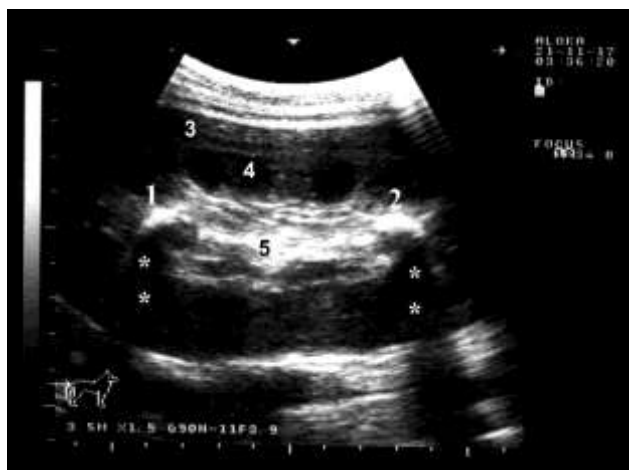

Fig. 3: Nephrolithiasis (1 and 2) in a female camel with red urine for a 6-month period. 3, renal cortex; 4, renal medulla; 5, renal sinus. Stars point to acoustic shadowing under the calculi.

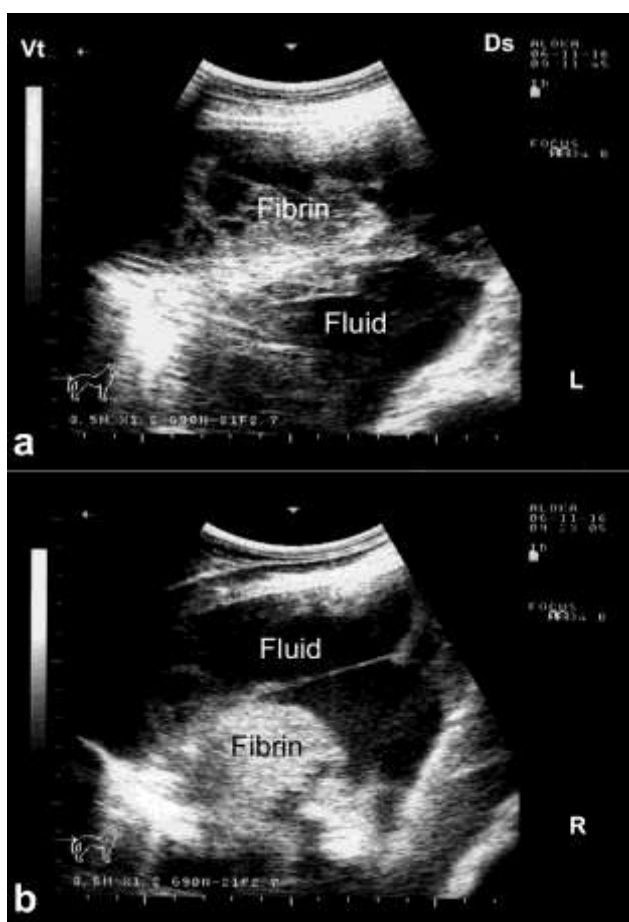


Fig. 4: Ultrasonographic findings in a female camel calf with fibrinous pleuropneumonia at both left (L; a) and right (R; b) lungs. Massive fibrin networks are apparent stretched and floating in a heterogeneous fluid.

Use of Ultrasound in Detecting Thoracic Diseases

In veterinary literature, various pathological lesions including hydatidosis, pneumonia, pleuritis, pulmonary abscesses, pneumoconiosis, bronchitis, linear scars, tubercle nodules and primary bronchioalveolar adenocarcinoma have been described in the lungs of camels. In addition to reported lesions, pulmonary affections have been detected in specific camel diseases

such as tuberculosis, camel pox, respiratory sonobe disease and aspergillosis (Bekele 1999; Kojouri et al. 2014). Ultrasonography of camels with pneumonia shows lung consolidation accompanied sometimes by pleural effusions. The non-ventilated lung tissue has an echotexture resemble that of the liver. In cases with drenching pneumonia, ultrasonographic examination of the lung tissue reveals hypoechogenic areas on the superficial part of the pulmonary tissue (Tharwat and Al-Sobayil 2016b). Ultrasonographic examination of with pulmonary abscessation reveals hyperechogenic pleura, medium echogenicity of the pulmonary parenchyma with a liver-like appearance. The lesion surrounding is shown as a skinny hyperechogenic rim and acoustic enhancement is imaged just below the lesion (Tharwat and Al-Sobayil 2016b). In advanced cases of pleuritis, thoracic ultrasonography revealed bilateral heterogeneous pleural effusions with fibrin threads. In another severe case, thoracic ultrasonography revealed a considerable amount of heterogeneous fluid with a large fibrin net at both the left and right pleural sacs (Fig. 4). Results of postmortem examination included: massive adhesions between the pleurae and costal arch, a large amount of serosanguineous fluid in both pleural sacs and consolidation of the anterior part of the left lung (Tharwat and Al-Sobayil 2016b).

Conclusion

In camels, the use of ultrasound in the past was limited to examining reproductive disorders. Over the past decade, light has been shed on the role of ultrasound in diagnosing various non-reproductive disorders affecting dromedary camels. The procedure supplemented the field and lab tests through acquiring extra data on these affections for the early detection. This review especially confirms the diagnostic value of ultrasound in dromedary camels in verification of various diseases affecting the cardiovascular, respiratory, gastrointestinal, hepatic and urinary systems. The methodology can also be implemented for deciding the prediction and therapy results in different affections. It is finally advised that the veterinarian should use the ultrasound in its daily routine with diseased camels before taking a decision for either medical treatment or even before the more invasive surgical interference.

Acknowledgments

The author extends his appreciation to the Deputyship for Research & Innovation, Ministry of Education, Saudi Arabia for funding this research work through the project number (QU-IF-2-1-3-25367). The author also thanks Qassim University for technical support

REFERENCES

- Ali A, Derar D, Al-Sobayil F, Tharwat M, Ahmed F and Khodeir M, 2018. Adenocarcinoma in the genital tract of female dromedary camels. *Journal of Camel Practice and Research* 25: 181-187. <https://doi.org/10.5958/2277-8934.2018.00025.5>
- Aljameel MA, Halima MO, ElTigani-Asil AE, Abdalla AS and Abdellatif MM, 2014. Liver abscesses in dromedary camels: Pathological characteristics and aerobic bacterial aetiology. *Open Veterinary Journal* 4: 118-123.

- Al-Sobayil F, Ali A, Derar D, Tharwat M, Ahmed F and Khodeir M, 2018. Tumors in dromedary camels: prevalence, types and locations. *Journal of Camel Practice and Research* 25: 189-197. <https://doi.org/10.5958/2277-8934.2018.00026.7>
- Andersen CA, Holden S, Vela J, Rathleff MS and Jensen MB, 2019. Point-of-Care Ultrasound in General Practice: A Systematic Review. *Annals of Family Medicine* 17: 61-69. <https://doi.org/10.1370/afm.2330>
- Bekele T, 1999. Studies on the Respiratory Disease 'Sonbobe' in Camels in the Eastern Lowlands of Ethiopia. *Tropical Animal Health and Production* 31: 333-345. <https://doi.org/10.1023/A:1005290523034>
- Belina D, Giro B, Ashenafi H, Demissie T and Muktar Y, 2015. Review on camel liver pathology and its major diagnostic approaches. *Global Journal of Veterinary Medicine and Research* 3: 68-79. <https://doi.org/10.13140/RG.2.1.4379.8646>
- Braun U, Gerspach C, Volz C, Boesiger M, Hilbe M and Nuss K, 2023. A retrospective review of small intestinal intussusception in 126 cattle in Switzerland. *Veterinary Record Open* 10: e58. <https://doi.org/10.1002/vro2.58>
- Crilly JP, 2022. How useful is transthoracic ultrasonography for detecting ovine pulmonary adenocarcinoma in sheep? *Veterinary Record* 191: 119-121. <https://doi.org/10.1002/vetr.2106>
- Díaz-Gómez JL, Mayo PH and Koenig SJ, 2021. Point-of-Care Ultrasonography. *New England Journal of Medicine* 385: 1593-1602. <https://doi.org/10.1056/NEJMra1916062>
- El-Shafaey ES, Sadan M and Refaai W, 2020. Superficial swellings in camels (*Camelus dromedarius*): Clinical and ultrasonographic findings. *Journal of Veterinary Medical Science* 82: 1346-1353. <https://doi.org/10.1292/jvms.20-0163>
- Fowler ME, 2010. *Medicine and Surgery of Camelids*. 3rd ed. Blackwell Publishing, Ames.
- Hawkins A, Chapman L, Meter M and Smith RK, 2022. Ultrasound-guided tenoscopic decompression of digital sheath synovioceles in 10 horses. *Veterinary Surgery* 51: 311-319. <https://doi.org/10.1111/vsu.13751>
- Jilo C, Abdela N, Dabasa G and Elias M, 2017. Camel Trypanosomiasis: A Review on Past and Recent Research in Africa and Middle East Kula. *American-Eurasian Journal of Scientific Research* 12: 13-20. <https://doi.org/10.5829/idosi.ajejsr.2017.13.20>
- Kojouri GA, Nourani H, Sadeghian S, Imani H and Raisi A, 2014. Pathological findings of slaughtered camels' (*Camelus dromedaris*) kidneys in Najaf-Abad, Iran. *Veterinary Research Forum* 5: 231-235.
- Nielsen MB, Søgaard SB, Bech Andersen S, Skjoldbye B, Hansen KL, Rafaelsen S, Nørgaard N and Carlsen JF, 2021. Highlights of the development in ultrasound during the last 70 years: A historical review. *Acta Radiologica* 62: 1499-1514. <https://doi.org/10.1177/02841851211050859>
- Sadan M, El-Shafaey ES and Al-Sobayil F, 2020. Diagnosis and treatment of foreign bodies swallowing syndrome in camels (*Camelus dromedarius*) with special reference to the role of mineral deficiency. *Journal of Veterinary Medical Science* 82: 1097-1103. <https://doi.org/10.1292/jvms.19-0621>
- Salem MA, El-Deeb WM, Zaghawa AA, Housawi FM and Alluwaimi AM, 2019. Investigation of Mycobacterium paratuberculosis in Arabian dromedary camels (*Camelus dromedarius*). *Veterinary World* 12: 218-223. <https://doi.org/10.14202/vetworld.2019.218-223>
- Sary R, Khalil K, Sindi RA, Mohamed RH, Hussein HA, Eid RA, Samir H, Alkahtani MM, Swelum AA and Ahmed AE, 2022. Characteristics of ultrasound and magnetic resonance imaging of normal testes and epididymis besides angiography of testicular artery in dromedary camel. *Frontiers in Veterinary Science* 9: 899570. <https://doi.org/10.3389/fvets.2022.899570>
- Scheemaeker S, Vandermeulen E, Ducatelle R, Stammeleer L, Devriendt N, Roggeman T and Daminet S, 2023. Ultrasound-guided core needle biopsy in dogs with thyroid carcinoma. *Veterinary and Comparative Oncology* 210: 349-356. <https://doi.org/10.1111/vco.12895>
- Shimizu N, Hamaide A, Soliveres E, Heimann M, Noel S and Bolen G, 2021. Ultrasound-guided transurethral urinary bladder biopsy using an endoscopic biopsy forceps in dogs: 27 cases (2016-2019). *Journal of Small Animal Practice* 62: 788-794. <https://doi.org/10.1111/jsap.13344>
- Tharwat M, Al-Sobayil F, Ali A and Buczinski S, 2012a. Transabdominal ultrasonographic appearance of the gastrointestinal viscera of healthy camels (*Camelus dromedarius*). *Research in Veterinary Science* 93: 1015-1020. <https://doi.org/10.1016/j.rvsc.2011.12.003>
- Tharwat M, Al-Sobayil F, Ali A and Buczinski S, 2012b. Ultrasonographic evaluation of abdominal distension in 52 camels (*Camelus dromedarius*). *Research in Veterinary Science* 93: 448-456. <https://doi.org/10.1016/j.rvsc.2011.07.009>
- Tharwat M, Al-Sobayil F, Ali A, Wittek T and Floeck M, 2012c. Percutaneous ultrasound-guided portocentesis in camels (*Camelus dromedaries*). *Journal of Camel Practice and Research* 19: 193-196.
- Tharwat M, Al-Sobayil F, Ali A, Hashad M and Buczinski S, 2012d. Clinical, ultrasonographic, and pathologic findings in 70 camels (*Camelus dromedarius*) with Johne's disease. *Canadian Veterinary Journal* 53: 543-548.
- Tharwat M, Al-Sobayil F, Ali A and Buczinski S, 2012e. Ultrasonography of the liver and kidneys of healthy camels (*Camelus dromedarius*). *Canadian Veterinary Journal* 53: 1273-1278.
- Tharwat M, Al-Sobayil F, Ali A and Buczinski S, 2012f. Echocardiography of the normal camel (*Camelus dromedarius*) heart: technique and cardiac dimensions. *BMC Veterinary Research* 8: 130. <https://doi.org/10.1186/1746-6148-8-130>
- Tharwat M, 2013a. Ultrasonographic findings in camels (*Camelus dromedarius*) with trypanosomiasis. *Journal of Camel Practice and Research* 20, 283-287.
- Tharwat M, 2013b. Ultrasonography of the lungs and pleura in healthy camels (*Camelus dromedarius*). *Acta Veterinaria Hungarica* 61: 309-318. <https://doi.org/10.1556/AVet.2013.019>
- Tharwat M, Ali A, Al-Sobayil F and Buczinski S, 2013. Ultrasound-guided collection of peritoneal fluid in healthy camels (*Camelus dromedarius*) and its biochemical analysis. *Small Ruminant Research* 113: 307-311. <https://doi.org/10.1016/j.smallrumres.2013.04.002>
- Tharwat M and Al-Sobayil F, 2016a. Ultrasonographic findings in camels (*Camelus dromedarius*) with abdominal disorders. *Journal of Camel Practice and Research* 23: 291-299. <https://doi.org/10.5958/2277-8934.2016.00049.7>
- Tharwat M and Al-Sobayil F, 2016b. Ultrasonographic findings in camel calves (*Camelus dromedarius*) with thoracic affections. *Journal of Camel Practice and Research* 23: 287-290. <https://doi.org/10.5958/2277-8934.2016.00048.5>
- Tharwat M, Al-Sobayil F, Ali A, Derar D and Khodeir M, 2017. Renal cell carcinoma in a female Arabian camel: clinical, hematobiochemical, ultrasonographic and pathologic findings. *Journal of Camel Practice and Research* 24: 61-66. <https://doi.org/10.5958/2277-8934.2017.00009.1>
- Tharwat M, El-Shafaey E, Sadan M, Ali A, Al-Sobayil F and Al-Hawas A, 2018a. Omaso-abomasal adenocarcinoma in a female Arabian camel (*Camelus dromedarius*). *Journal of Applied Animal Research* 46: 1268-1271. <https://doi.org/10.1080/09712119.2018.1495644>
- Tharwat M, Sadan M, El-Shafaey E, Al-Hawas A and Saeed EMA, 2018b. Unilateral nephrectomy in a female dromedary camel with pyelonephritis caused by *Staphylococcus*

- lugdunensis*. Pakistan Veterinary Journal 38: 116-118. <https://doi.org/10.29261/pakvetj/2018.024>
- Tharwat M, Sadan M, El-shafaey, El-hassan saeed E and Al-hawas A, 2018c. Bilateral renal abscessation and chronic active pyelonephritis in a male camel (*Camelus dromedarius*) caused by *Escherichia coli*. Journal of Veterinary Medical Science 80: 778–783. <https://doi.org/doi:10.1292/jvms.17-0484>
- Tharwat M, 2019. Chronic peritonitis in dromedary camels: clinical, hematobiochemical, ultrasonographic and pathologic findings. Journal of Camel Practice and Research 26, 169-172. <https://doi.org/10.5958/2277-8934.2019.00026.2>
- Tharwat M, 2020a. Ultrasonography of the abdomen in healthy and diseased camels (*Camelus dromedaries*). Journal of Applied Animal Research 48: 300-312. <https://doi.org/10.1080/09712119.2020.1788035>
- Tharwat M, 2020b. Ultrasonography of the liver in healthy and diseased camels (*Camelus dromedaries*). Journal of Veterinary Medical Science 82: 399–407. <https://doi.org/10.1292/jvms.19-0690>
- Tharwat M, 2020c. Ultrasonography of the kidneys in healthy and diseased camels (*Camelus dromedaries*). Veterinary Medicine International 2020: 7814927. <https://doi.org/10.1155/2020/7814927>
- Tharwat M, 2021. Obstructive urolithiasis in dromedary camels: clinical, ultrasonographic and postmortem findings. Journal of Camel Practice and Research 28: 85-93. <https://doi.org/10.5958/2277-8934.2021.00013.8>
- Turner ZB, Lima FS, Conley AJ, McNabb BR, Rowe JD, Garzon A, Urbano TM, Morris CM and Pereira RV, 2023. Cystic ovarian disease in dairy cattle: Diagnostic accuracy when using B-mode and color Doppler ultrasound. Journal of Dairy Science 106: 3411-3420. <https://doi.org/10.3168/jds.2022-22498>
- Wernery U and Kaaden OR, 2002. Infectious Diseases in Camelids. 2nd Ed, Blackwell Germany