



Pyometra in the Queen: Evaluation of Different Methods of Treatment

Sulake Fadhil Al-Zubaidi¹, Ghusoon A.A. Alneamah², Ali Saleh Mahdi¹ and Abdulraheem Abduljalil Wali³

¹Surgery and Obstetric Department, College of Veterinary Medicine, Al-Qasim Green University, Iraq

²Pathology and Poultry Diseases Department, College of Veterinary Medicine, Al-Qasim Green University, Iraq

³Veterinary Directorate, Department of Small Animal, Baghdad Central Veterinary Hospital, Baghdad, Iraq

*Corresponding author: sulakeobst@vet.uoqasim.edu.iq

Article History: 23-190

Received: 28-April-23

Revised: 13-Jun-23

Accepted: 15-Jun-23

ABSTRACT

Pyometra is a common disease of female cats (queens) characterized by endometrial hyperplasia with cystic dilation of endometrial glands and accumulation of the neutrophil-rich exudate in the uterine lumen. In this study, 20 queens with the age range of 10 to 108 months (average 26 months) and diagnosed with pyometra (open and closed) between January 2019 and January 2021 were divided into four groups A, B, C and D, with five queens in each group. A first dose of Alizin® was given at 10mg/kg (S/C) to animals of groups A, B and C. In group A, the second dose of Alizin® was given 24hrs later while monitoring for vaginal discharge. In group B, upon notice of vaginal discharge at 24hrs, a dose of PGF₂α was given at 1.0mcg/kg BW (S/C) which eventually stopped the discharge. In group C, upon notice of vaginal discharge at 24hrs, a dose of Cytotec® was given intravaginally as 100mcg/cat. Group D was subjected to ovariohysterectomy and no complication was noted for 7 days post operation; on the 14th day, sutures were removed, and the surgical site healed completely. Vaginal discharge was noticed post Alizin® administration in groups A, B and C. Responses in three groups were observed 24 and 48hrs post treatment. In groups B and C, there was evidence of higher evacuated uterine pus compared to group A. Group C was better with no evidence of rapid respiration compared to groups B and A. There was evidence of general health response with the maximum resumption of feeding in groups B and C. In conclusion, the current study elucidated a different dimension for treating pyometra with an advantage of recovery and complete healing coupled with the response of maximum feeding for groups treated with Alizin in combination with PGF₂α or Misoprostol.

Key words: Pyometra, Aglepristone, PGF₂α, Cytotec, Ovariohysterectomy.

INTRODUCTION

Pyometra is a common reproductive problem in female cats (Carlson et al. 2022) and bitches (Rocha et al. 2022). It is characterized by acute or chronic suppurative bacterial infection causing inflammation of the uterus (Rocha et al. 2022). There is endometrial hyperplasia with cystic dilation of endometrial glands and accumulation of a neutrophil-rich exudate in the uterine lumen. The etiological agents responsible for this problem include *Escherichia coli*, *Streptococcus*, *Staphylococcus*, *Klebsiella*, *Pasteurella*, *Pseudomonas* and *Proteus* species (Davidson and Black 2022). The major factors associated with pyometra include ovarian hormones which play an important role in pathogenesis of this disease (Hagman 2022).

The pathogenesis of pyometra is related to the effects of progesterone and it is the main reason for development

of the disease in the luteal phase or during pseudo-pregnancy, which is a phase of progesterone dominance and lasts approximately for 40 days (Hagman 2022). A common clinical finding in most cases of pyometra is the mucopurulent to hemorrhagic vaginal discharge (Soumya et al. 2022), but in an open cervix pyometra blood-stained purulent vaginal discharge may be the only clinical sign. Endotoxemia as a result of resorption of bacterial toxins from the uterine lumen into the circulation in the closed cervix pyometra can also be seen in rare cases. Additionally, other non-specific clinical signs such as anorexia, vomiting, lethargy, loss of weight and unkempt appearance can also be observed (Garcés et al. 2022).

The most important diagnostic tool in cases of pyometra is the abdominal examination through ultrasonography (Aguilar et al. 2022). The uterine horn typically appear distended with hypo/hyperechoic fluid with or without flocculation. The uterine wall often

Cite This Article as: Al-Zubaidi SF, Alneamah GAA, Mahdi AS and Wali AA, 2024. Pyometra in the queen: Evaluation of different methods of treatment. International Journal of Veterinary Science 13(1): 80-84. <https://doi.org/10.47278/journal.ijvs/2023.068>

appears thickened with irregular edges and small hypoechoic areas consistent with cystic changes of the endometrial glands. The pyometra can also be segmental or diffuse in nature (Carlson et al. 2022). Cytology of the uterine or vaginal discharge is likely to reveal degenerative neutrophils and phagocytized bacteria. Treatment usually ranges from correction of fluid deficits and proper administration of antibiotics against bacterial organisms to removal of infected uterine contents (Davidson and Black 2022). Other management practices include ovariohysterectomy (Fieni et al. 2014) or use of prostaglandin F_{2α} (Mitacek et al. 2014; Attard 2022). Medical (Goericke-Pesch 2010; Gogny and Fiéni 2016) or surgical treatment can be applied depending on the condition of the patient, while broad-spectrum antibiotic therapy is also instituted following diagnosis of the disease (Agudelo 2005; Hollinshead and Krekeler 2016). The present study was undertaken to investigate comparative efficacy of four different protocols for the treatment of pyometra in female cats (queens).

MATERIALS AND METHODS

Ethics

This study was performed in accordance with the local Animal Welfare Committee's ethical guidelines, and all procedures were carried out pursuant to the legislation on animal care and the guidelines on Animal Welfare of the Surgery and Obstetric Department, College of Veterinary Medicine, Al-Qasim Green University, Baghdad, Iraq.

Study Location

The present study was conducted at the Department of Surgery and Obstetric, College of Veterinary Medicine, Al-Qasim Green University, Baghdad Central Veterinary Hospital and private clinics located in Baghdad, Iraq.

Animal model

A total of 20 queens (female cats) with the age range between 10 to 108 months (average 26 months) and diagnosed to be suffering with pyometra (open and closed) between January 2019 and January 2021 were selected for the present study. These queens belong to Persian, Himalayan, Scottish and mixed breeds. They were randomly divided into four experimental groups A, B, C and D, with five queens in each group. The veterinary ultrasound device "Sonosite-180 (USA)" fitted with a micro convex probe (3.5-5.0 MHz frequency) was used after proper clipping of the area to diagnosis pyometra.

Treatment groups

The first dose of Aglepristone (Alizin®) was given at 10.0mg/kg BW (S/C) to queens of groups A, B and C. In group A, the second dose of Alizin® was given 24hrs later while monitoring for vaginal discharge. In group B, upon notice of vaginal discharge at 24hrs, a dose of PGF_{2α} was given at 1.0mcg/kg BW (S/C). In group C, upon notice of vaginal discharge at 24hrs, a dose of Cytotec® was given intravaginally as 100mcg/cat. Animals of group D were subjected to ovariohysterectomy. Experimental cats of all groups were given PEN/STREP® 400 (Dutch Farm International BV, Nieuw

Walden, Holland) in at a dose of 1.0mL per 10 kg body weight for 3-5 days.

Ovariohysterectomy

Animals of group D were subjected to ovariohysterectomy under general anesthesia induced with Xylazine 2% at 0.15 ml/kg BW dose (Woerden, Holland) and maintained with ketamine 10% at 15mg/kg BW dose (Woerden, Holland). After restraining the animal in dorsal recumbency for a ventral midline celiotomy, ventral abdomen was closely clipped, and aseptic surgery was performed. Ovariohysterectomy was performed and both ovaries and horns of the uterus were removed (Fig. 1). No complication was noted after the operation and the sutures were removed on the 14th day, when the surgical site was healed completely.

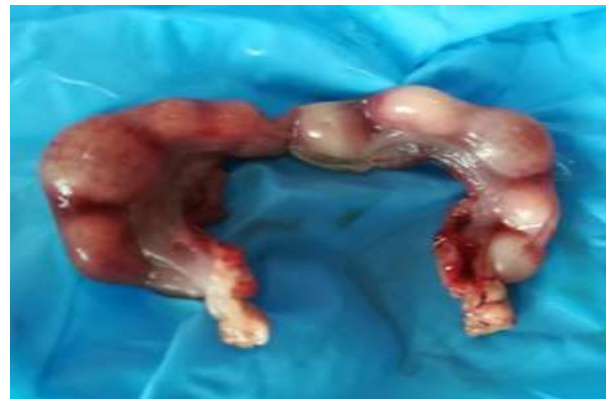

Fig. 1: Uterus of queen with pyometra after ovariohysterectomy.

Histopathological study

The samples of uterine tissue were collected from the queens with pyometra and processed for histopathological examination. Tissue samples were fixed in 10% formaldehyde solution, and then dehydrated using increasing concentrations of ethanol. After cleaning with xylene, tissue samples were impregnated with paraffin wax, heated and blocked by pouring in embedded models. Blocks were cut by microtome into 4-5µm thick sections, washed in the water bath and left within the oven for dewaxing. Then sections were stained with hematoxylin and eosin (H and E) and examined under light microscope, as described by Bancroft and Gamble (2008).

RESULTS

Clinical signs

Vaginal discharge was noticed post Alizin® administration in female cats of groups A, B and C. This was then immediately followed by administration of second Alizin® dose, PGF_{2α} and Cytotec® in groups A, B and C, respectively. Responses in three groups were observed 24 and 48hrs post treatment. In animals of groups B and C, there was evidence of higher evacuated uterine pus as compared to group A. The general health of animals of Group C was better with no evidence of rapid respiration compared to animals of groups B and A (Table 1). There was evidence of a general health response with the maximum resumption of feeding in cats of groups B and C.

Table 1: Clinical signs and response of different groups after treatment

Groups	Vaginal discharge	Evacuation of uterine pus	Animal health response to feeding	Rapid respiration
A	Noticed	Moderate	Fair	Fairly rapid
B	Noticed	High	Maximum	Fairly rapid
C	Noticed	High	Maximum	Not rapid
D	Noticed	-	-	-

Histopathological study

The results of most of the examined sections showed severe cystic hyperplasia and actasia of endometrium, with the presence of cellular debris and inflammatory cells inside the glands lumen (Fig. 2A). Also, there was severe vacuolation in the endometrium and glandular epithelia, which contained several layers with highly inflammatory cells infiltration (Fig. 2B), while other sections showed severe vacuolation in the endometrium with inflammatory cells infiltration, mainly neutrophils (Fig. 2C&D). However, in severe cases, the lesion showed necrosis in the endometrial glands with inflammatory cells infiltration (Fig. 3A) and severe edema and inflammatory cells infiltration in the myometrium that caused atrophy of the muscle fibers (Fig. 3B).

DISCUSSION

Pyometra is a uterine inflammatory disorder characterized by cystic endometrial hyperplasia (Agudelo 2005; Carlson et al. 2022). The prevalence of pyometra increases with age in sexually intact female cats and it mainly occurs after parturition. Additionally, it has been suggested that the disease is common in queens older than three to five years (Nak et al. 2009; Hagman 2022). However, it is speculated that the disease is related to degenerative changes in the uterus or other conditions such as ovarian pathologies or uterine neoplasia, predisposing development of pyometra. But younger cats have also been reported to be affected with this problem.

In the present study, there was evidence of vaginal discharge post Alizin injection in female cats of groups A, B and C. The results of this study are in harmony with those reported earlier (Binli 2022), where vaginal discharge was observed in animals treated with Alizin injection; the vaginal discharge varied from yellowish-green or greenish brown to brown in color. Similar observations were reported by Zhelavskiy and Shunin (2017) and Hagman (2018). Additionally, just like in the recent study (Binli 2022), vaginal discharge began to appear within 24hr post Alizin injection. A lot of

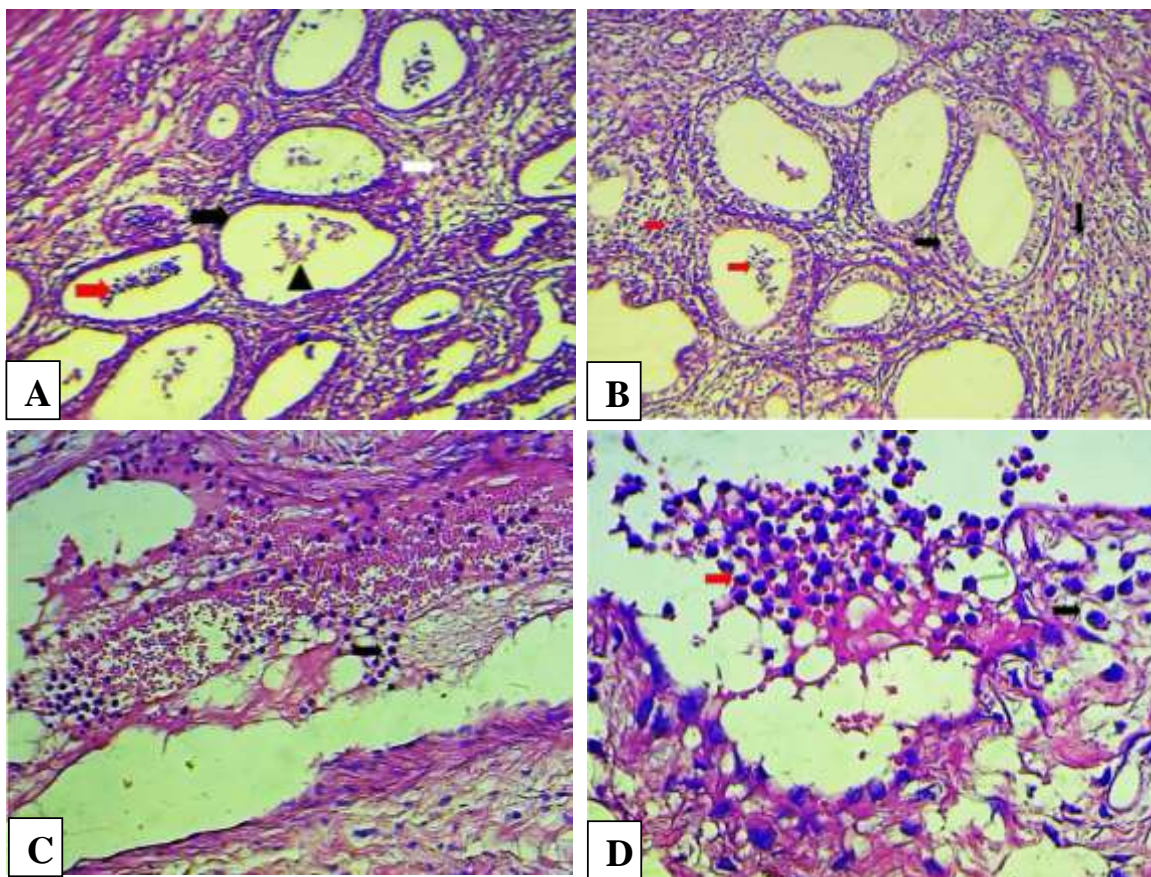


Fig. 2: Histopathological sections of queen uterus showing A: Severe cystic endometrium hyperplasia and ectasia (black arrow), with presence of amorphous eosinophilic material in glands lumen (head arrow), and extensive interstitial inflammatory cells infiltration (white arrow) (H&E stains, 100x). B: Severe vacuolation in the endometrium and glandular epithelia (black arrow) which contain several layers, and highly inflammatory cells infiltration (red arrow) (H&E stains, 200x). C: Severe vacuolation in the endometrium (black arrow), with inflammatory cells infiltration mainly neutrophils (red arrow) (H&E stains, 400x). D: Severe vacuolation in the endometrium (black arrow), with inflammatory cells infiltration mainly neutrophils (red arrow) (H&E stains, 400x).

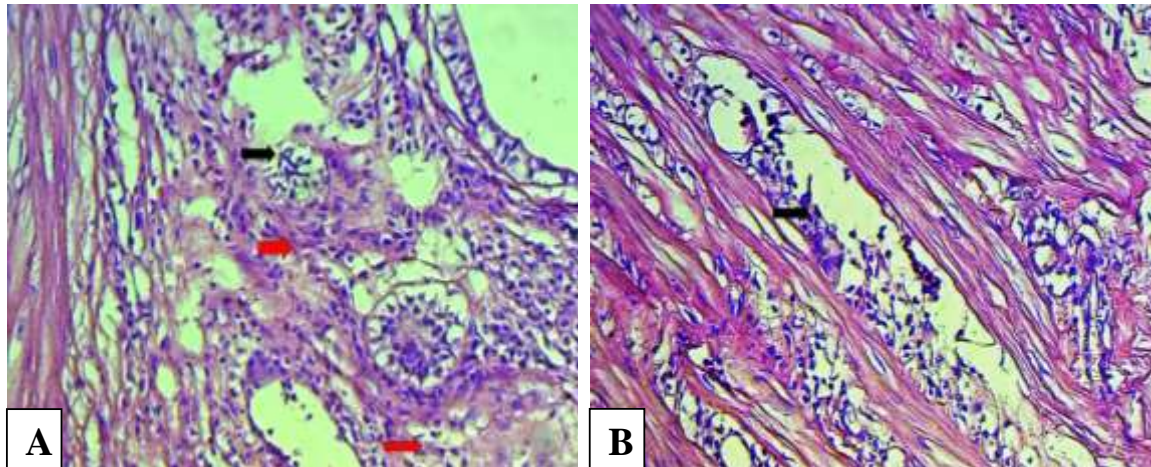


Fig. 3: Histopathological section of queen uterus showing: A) Necrosis in the endometrial glands (red arrow) with inflammatory cells infiltration (black arrow) (H&E stains, 200x). B) Severe edema and inflammatory cells infiltration in the myometrium that caused atrophy of the muscle fibers (black arrow) (H&E stains, 400x).

speculations have been documented, cautioning the use of Alizin in the treatment of pyometra, but intriguingly, other reports have indicated that the application of Alizin does not in any way affect ovulation in treated animals (Attard 2022). In the report by Socha et al. (2021), ovulation occurred in all Alizin treated bitches, while Contri et al. (2015) reported that 80% of bitches became pregnant after aglepristone treatment. But in contrast to our findings and various reports, some animals treated with Alizin have indicated an extended duration of sexual behavior, thereby delayed the resumption of oocyte meiosis and inhibited its progression (Bladowska et al. 2018). The variations in these results might be attributed to different experimental models, doses of the drug and other hormonal interactions.

The current study indicated a moderate evacuation of uterine pus in cats of group A (treated with Alizin), while a higher uterine pus evacuation was recorded in animals treated with PGF₂ α and Misoprostol (groups B and C, respectively). This finding is consistent with a previous report, indicating that specific treatment with PGF₂ α evacuates the uterine pus and stimulates immunity (Bagri 2022). The harmony in this finding is associated with the fact that PGF₂ α possesses luteolytic and uterotonic activity (Verstegen et al. 2008) which makes it a better option for treating pyometra even at repeated doses. However, there are reports indicating that the clinical status of animals treated with PGF₂ α does not usually start to improve until at least 48hr post treatment (Bagri 2022). The current study is also in harmony with that of Sanchez-Morales et al. (2022), who have stipulated that Misoprostol stimulates uterine contractions and causes the uterine contents to be expelled at a rate of about 94% and higher. These findings might also be linked with the fact that Misoprostol has many advantages over other agents such as osmotic dilators, prostaglandins and mifepristone. The use of Misoprostol has been found to improve cervical dilatation, reduce the need of further dilatation and ease of dilatation without any complication (Chidambaram et al. 2022).

Clinical examination of cats in the present study showed that respiration was fairly rapid in groups treated with Alizin and PGF₂ α (groups A and B, respectively), while the group treated with Misoprostol (group C) did

not show rapid respiratory signs. This finding is supported by the result of Hassan et al. (2022), who demonstrated that administration of Misoprostol significantly decreases rapid respiration.

Contrarily, some previous studies indicated non-significant differences in the respiratory outcomes after delivering Misoprostol. According to Elboghdady et al. (2022), administration of Misoprostol in the form of Cytotec® showed non-significant differences in respiratory status in newborns. However, such controversies could be the result of low quality of evidence caused by the small study samples and different Misoprostol doses in such studies. The present study further elucidated that the response to feeding was maximum in groups treated with PGF₂ α and Misoprostol (groups B and C, respectively), while a fair response was recorded for the group treated with Alizin alone (group A). In the current study, animals subjected to ovariectomy in group D showed no complication post-operative, the surgical site healed completely, indicating a good prognosis.

Conclusion

In conclusion, the current study elucidated a different dimension for treating pyometra with an advantage of recovery and complete healing coupled with the positive response by animals treated with Alizin in combination with PGF₂ α or Misoprostol.

Authors' contribution

Sulake Fadhil Al-Zubaidi conceived the presented idea. The experimental work was carried out by Sulake Fadhil Al-Zubaidi, Ali Saleh Mahdi and Abduraheem Abduljalil Wali. Histopathological study was performed by Ghusoon A.A. Alneamah. Sulake Fadhil Al-Zubaidi wrote the manuscript with input from all authors. All authors reviewed and approved the final manuscript.

REFERENCES

- Agudelo CF, 2005. Cystic endometrial hyperplasia-pyometra complex in cats. A review. *Veterinary Quarterly* 27: 173–182. <https://doi.org/10.1080/01652176.2002.9695198>

- Aguilar LA, Leach K, Watson MK, Wang C and Rivera S, 2022. Medical management of open pyometra in a giant panda (*Ailuropoda melanoleuca*). *Veterinary Record* 10(2): 300. <https://doi.org/10.1002/vrc2.300>
- Attard S., 2022. Effectiveness of a modified administration protocol for the medical treatment of feline pyometra. *Veterinary Sciences* 9(10): 517. <https://doi.org/10.3390/vetsci9100517>
- Bagri HK, 2022. An overview on etiopathogenesis of canine pyometra and its management. *The Pharma Innovation Journal* 11(6): 1184-1188. <https://dx.doi.org/10.22271/tpi>
- Bancroft JD and Gamble M, 2008. *Theory and Practice of Histology Techniques*. Churchill Livingstone Elsevier, London, UK. p83-134.
- Binli F, 2022. The efficacy of a 3 β -hydroxysteroid dehydrogenase inhibitor for the termination of mid-term pregnancies in dogs. *Animals* 12(18): 2475. <https://doi.org/10.3390/ani12182475>
- Bładowska K, Barański W and Janowski TE, 2018. Preovulatory progesterone secretion terminates the duration of reproductive behavior during heat in the bitch. *Polish Journal of Veterinary Sciences*.21(3): 615-622. <https://doi.org/10.24425/124297>
- Carlson AK, Ramsay EC, Sun X, Chaffins D and Sula MM, 2022. Endometrial hyperplasia and pyometra in captive lions (*Panthera leo*) and tigers (*Panthera tigris*). *Veterinary Pathology*, 59(6): 1003–1011. <https://doi.org/10.1177/03009858221109094>
- Chidambaram V, Pallavee P, Samal R and Ghose S, 2022. A randomised comparative study of sublingual and vaginal misoprostol for cervical priming before minor gynaecological procedures. *Journal of Obstetrics and Gynaecology* 42(6): 2297-2301. <https://doi.org/10.1080/01443615.2022.2042224>
- Contri A, Gloria A, Carluccio A, Pantaleo S and Robbe D, 2015. Effectiveness of a modified administration protocol for the medical treatment of canine pyometra. *Veterinary Research Communications* 39: 1–5. <https://doi.org/10.1007/s11259-014-9619-9>
- Davidson J and Black D, 2022. Pyometra. In: Aronson LR (ed), *Small Animal Surgical Emergencies*, 2nd Ed, Wiley-Blackwell, pp: 534-540. <https://doi.org/10.1002/9781119658634.ch48>
- Elboghady AA, Esmael ME and Hossam H, 2022. Role of Misoprostol (PGE1) before elective caesarean section in decreasing transient tachypnea of the newborn (TTN). *The Medical Journal of Cairo University* 90(6): 1155-1161. <https://doi.org/10.21608/mjcu.2022.257406>
- Fieni F, Topie E and Gogny A, 2014. Medical treatment for pyometra in dogs. *Reproduction in Domestic Animals* 49: 28-32. <https://doi.org/10.1111/rda.12302>
- Garcês A, Soeiro V, Lóio S and Pires I, 2022. Description of a closed pyometra on a wild boar (*Sus scrofa*, Linnaeus 1758). *Veterinarska Stanica* 53(3): 343-346. <https://doi.org/10.46419/vs.53.3.3>
- Goericke-Pesch S, 2010. Reproduction control in cats: New developments in non-surgical methods. *Journal of Feline Medicine and Surgery* 12(7): 539–546. <https://doi.org/10.1016/j.jfms.2010.05.005>
- Gogny A and Fiéni F, 2016. Aglepristone: A review on its clinical use in animals. *Theriogenology* 85: 555–566. <https://doi.org/10.1016/j.theriogenology.2015.10.010>
- Hagman R, 2018. Pyometra in small animals. *Veterinary Clinics of North America: Small Animal Practice* 48(4): 639-661. <https://doi.org/10.1016/j.cvsm.2018.03.001>
- Hagman R., 2022. Pyometra in Small Animals 2.0. *The Veterinary Clinics of North America: Small Animal Practice* 52(3): 631–657. <https://doi.org/10.1016/j.cvsm.2022.01.004>
- Hassan A, Mahmoud NA and Elhawary MO, 2022. Vaginal misoprostol before elective caesarean section for preventing neonatal respiratory morbidity. *Evidence Based Women's Health Journal* 12(2): 149-56. <https://doi.org/10.21608/ebwhj.2021.109258.1159>
- Hollinshead F and Krekeler N, 2016. Pyometra in the queen: To spay or not to spay? *Journal of Feline Medicine and Surgery* 18: 21–33. <https://doi.org/10.1177/1098612X15623114>
- Mitacek MCG, Stornelli MC, Tittarelli CM, Favre RN, de la Sota RL and Stornelli MA, 2014. Cloprostenol treatment of feline open-cervix pyometra. *Journal of Feline Medicine and Surgery* 16(2): 177–179. <https://doi.org/10.1177/1098612X13498248>
- Nak D, Nak Y and Tuna B, 2009. Follow-up examinations after medical treatment of pyometra in cats with the progesterone-antagonist aglepristone. *Journal of Feline Medicine and Surgery* 11: 499–502. <https://doi.org/10.1016/j.jfms.2008.09.006>
- Rocha MFG, Paiva DDQ, Amando BR, Melgarejo CMA, Freitas AS, Gomes FIF, Ocadaque CJ, Costa CL, Guedes GMM, Lima-Neto RG, Cordeiro RA, Sidrim JJC and Castelo-Branco DSCM, 2022. Antimicrobial susceptibility and production of virulence factors by bacteria recovered from bitches with pyometra. *Reproduction in Domestic Animals* 57(9): 1063–1073. <https://doi.org/10.1111/rda.14181>
- Sanchez-Morales JE, Rodriguez-Contreras JL, Ruiz-Lara L, Ochoa-Torres B, Zaragoza M, and Padilla-Zuniga K, 2022. Cost analysis of surgical and medical uterine evacuation methods for first-trimester abortion used in public hospitals in Mexico. *Health Services Insights* 15: 11786329221126347. <https://doi.org/10.1177/11786329221126347>
- Socha P, Bładowska K, Zduńczyk S and Janowski T, 2021. Aglepristone administration in mid-proestrus reduces the LH peak but does not prevent ovulation in the bitch. *Animals* 11: 1922. <https://doi.org/10.3390/ani11071922>
- Soumya Y, Srinivas M, Kavitha K and Srinithi K, 2022. Antibigram of staphylococcal species isolated from canine pyometra. *The Pharma Innovation Journal* 11(7): 4399-4402. <https://dx.doi.org/10.22271/tpi>
- Verstegen J, Dhaliwal G and Verstegen-Onclin K, 2008. Mucometra, cystic endometrial hyperplasia, and pyometra in the bitch: Advances in treatment and assessment of future reproductive success. *Theriogenology* 70(3): 364-374. <https://doi.org/10.1016/j.theriogenology.2008.04.036>
- Zhelavskiy MM and Shunin IM, 2017. Clinical use of Aglepristone for treatment of open-cervix pyometra in cats. *Scientific Messenger of LNU of Veterinary Medicine and Biotechnologies. Series: Veterinary Sciences* 19(78): 9–12. <https://doi.org/10.15421/nvlvet7802>